

The care of patients with varicose veins and associated chronic venous diseases: Clinical practice guidelines of the Society for Vascular Surgery and the American Venous Forum

Peter Gloviczki, MD,^a Anthony J. Comerota, MD,^b Michael C. Dalsing, MD,^c Bo G. Eklof, MD,^d David L. Gillespie, MD,^e Monika L. Gloviczki, MD, PhD,^f Joann M. Lohr, MD,^g Robert B. McLafferty, MD,^h Mark H. Meissner, MD,ⁱ M. Hassan Murad, MD, MPH,^j Frank T. Padberg, MD,^k Peter J. Pappas, MD,^k Marc A. Passman, MD,^l Joseph D. Raffetto, MD,^m Michael A. Vasquez, MD, RVT,ⁿ and Thomas W. Wakefield, MD,^o Rochester, Minn; Toledo, Ohio; Indianapolis, Ind; Helsingborg, Sweden; Rochester, NY; Cincinnati, Ohio; Springfield, Ill; Seattle, Wash; Newark, NJ; Birmingham, Ala; West Roxbury, Mass; North Tonawanda, NY; and Ann Arbor, Mich

The Society for Vascular Surgery (SVS) and the American Venous Forum (AVF) have developed clinical practice guidelines for the care of patients with varicose veins of the lower limbs and pelvis. The document also includes recommendations on the management of superficial and perforating vein incompetence in patients with associated, more advanced chronic venous diseases (CVDs), including edema, skin changes, or venous ulcers. Recommendations of the Venous Guideline Committee are based on the Grading of Recommendations Assessment, Development, and Evaluation (GRADE) system as strong (GRADE 1) if the benefits clearly outweigh the risks, burden, and costs. The suggestions are weak (GRADE 2) if the benefits are closely balanced with risks and burden. The level of available evidence to support the evaluation or treatment can be of high (A), medium (B), or low or very low (C) quality. The key recommendations of these guidelines are: We recommend that in patients with varicose veins or more severe CVD, a complete history and detailed physical examination are complemented by duplex ultrasound scanning of the deep and superficial veins (GRADE 1A). We recommend that the CEAP classification is used for patients with CVD (GRADE 1A) and that the revised Venous Clinical Severity Score is used to assess treatment outcome (GRADE 1B). We suggest compression therapy for patients with symptomatic varicose veins (GRADE 2C) but recommend against compression therapy as the primary treatment if the patient is a candidate for saphenous vein ablation (GRADE 1B). We recommend compression therapy as the primary treatment to aid healing of venous ulceration (GRADE 1B). To decrease the recurrence of venous ulcers, we recommend ablation of the incompetent superficial veins in addition to compression therapy (GRADE 1A). For treatment of the incompetent great saphenous vein (GSV), we recommend endovenous thermal ablation (radiofrequency or laser) rather than high ligation and inversion stripping of the saphenous vein to the level of the knee (GRADE 1B). We recommend phlebectomy or sclerotherapy to treat varicose tributaries (GRADE 1B) and suggest foam sclerotherapy as an option for the treatment of the incompetent saphenous vein (GRADE 2C). We recommend against selective treatment of perforating vein incompetence in patients with simple varicose veins (CEAP class C₂; GRADE 1B), but we suggest treatment of pathologic perforating veins (outward flow duration ≥ 500 ms, vein diameter ≥ 3.5 mm) located underneath healed or active ulcers (CEAP class C₅-C₆; GRADE 2B). We suggest treatment of pelvic congestion syndrome and pelvic varices with coil embolization, plugs, or transcatheter sclerotherapy, used alone or together (GRADE 2B). (J Vasc Surg 2011;53:2S-48S.)

Abbreviations ACCP, American College of Chest Physicians; ASVAL, ablation sélective des varices sous anesthésie locale (ie, ambulatory selective varicose vein ablation under local anesthesia); AVF, American Venous Forum; AVVQ, Aberdeen Varicose Vein Questionnaire; CHIVA, cure conservatrice et hémodynamique de l'insuffisance veineuse en ambulatoire (ie, ambulatory conservative hemodynamic treatment of varicose veins); CI, confidence interval; CT, computed tomography; CVI, chronic venous insufficiency; CVD, chronic venous disease; DVT, deep venous thrombosis; EVLA, endovenous laser ablation; EVLT, endovenous laser therapy; FDA, U.S. Food and Drug Administration; GRADE, Grading of Recommendations, Assessment, Development, and Evaluation; GSV, great saphenous vein; HL/S,

From the Divisions of Vascular and Endovascular Surgery,^a Nephrology and Hypertension,^f and Preventive, Occupational and Aerospace Medicine,^l Mayo Clinic, Rochester; Jobst Vascular Center, Toledo^b; Indiana University School of Medicine, Indianapolis^c; University of Lund, Helsingborg^d; the School of Medicine and Dentistry, University of Rochester, Rochester^e; Lohr Surgical Specialists, Cincinnati^g; Southern Illinois University, Springfield^h; the University of Washington School of Medicine, Seattleⁱ; New Jersey Medical School, University of Medicine and Dentistry of New Jersey, Newark^k; the University of Alabama at Birmingham, Birmingham^l; VA Boston Healthcare System, West Roxbury^m; Venous Institute of Buffalo, North Tonawandaⁿ; and the University of Michigan Medical School, Ann Arbor.^o

Competing of interest: none.

Reprint requests. Peter Gloviczki, MD, Division of Vascular and Endovascular Surgery, Mayo Clinic, 200 First St SW, Rochester, MN 55905 (gloviczki.peter@mayo.edu).

0741-5214/\$36.00

Copyright © 2011 by the Society for Vascular Surgery.

doi:10.1016/j.jvs.2011.01.079

high ligation and stripping; ICP, intermittent compression pump; IVC, inferior vena cava; IVUS, intravascular ultrasonography; MPFF, micronized purified flavonoid fraction; MR, magnetic resonance; OR, odds ratio; PAPS, percutaneous ablation of perforators; PE, pulmonary embolism; PIN, perforate invaginate (stripping); PRO, patient-reported outcome; PTFE, polytetrafluoroethylene; QALY, quality-adjusted life-year; QOL, quality of life; RCT, randomized controlled trial; REVAS, recurrent varicose veins after surgery; RF, radiofrequency; RFA, radiofrequency ablation; RR, relative risk; SEPS, subsfascial endoscopic perforator surgery; SF-36, Short-Form 36-Item Health Survey; SFJ, saphenofemoral junction; SSV, small saphenous vein; STS, sodium tetradecyl sulfate; SVS, Society for Vascular Surgery; TIPP, transilluminated powered phlebectomy; VCSS, Venous Clinical Severity Score; VTE, venous thromboembolism

SUMMARY OF GUIDELINES FOR MANAGEMENT OF PATIENTS WITH VARICOSE VEINS AND ASSOCIATED CHRONIC VENOUS DISEASES

<i>Guideline No.</i>	<i>Guideline title</i>	<i>GRADE of recommendation</i>	<i>Level of evidence</i>
		1. Strong 2. Weak	A. High quality B. Moderate quality C. Low or very low quality
	1. Clinical examination		
1.1	For clinical examination of the lower limbs for chronic venous disease, we recommend inspection (telangiectasia, varicosity, edema, skin discoloration, corona phlebectatica, lipodermatosclerosis, ulcer), palpation (cord, varicosity, tenderness, induration, reflux, pulses, thrill, groin or abdominal masses), auscultation (bruit), and examination of ankle mobility. Patients should be asked for symptoms of chronic venous disease, which may include tingling, aching, burning, pain, muscle cramps, swelling, sensations of throbbing or heaviness, itching skin, restless legs, leg tiredness, and fatigue.	1	A
	2. Duplex scanning		
2.1	We recommend that in patients with chronic venous disease, a complete history and detailed physical examination are complemented by duplex scanning of the deep and superficial veins. The test is safe, noninvasive, cost-effective, and reliable.	1	A
2.2	We recommend that the four components of a complete duplex scanning examination for chronic venous disease should be visualization, compressibility, venous flow, including measurement of duration of reflux, and augmentation.	1	A
2.3	We recommend that reflux to confirm valvular incompetence in the upright position of the patients be elicited in one of two ways: either with increased intra-abdominal pressure using a Valsalva maneuver to assess the common femoral vein and the saphenofemoral junction, or for the more distal veins, use of manual or cuff compression and release of the limb distal to the point of examination.	1	A
2.4	We recommend a cutoff value of 1 second for abnormally reversed flow (reflux) in the femoral and popliteal veins and of 500 ms for the great saphenous vein, the small saphenous vein, the tibial, deep femoral, and the perforating veins.	1	B
2.5	We recommend that in patients with chronic venous insufficiency, duplex scanning of the perforating veins is performed selectively. We recommend that the definition of "pathologic" perforating veins includes those with an outward flow of duration of ≥ 500 ms, with a diameter of ≥ 3.5 mm and a location beneath healed or open venous ulcers (CEAP class C ₅ -C ₆).	1	B
	3. Plethysmography		
3.1	We suggest that venous plethysmography be used selectively for the noninvasive evaluation of the venous system in patients with simple varicose veins (CEAP class C ₂).	2	C
3.2	We recommend that venous plethysmography be used for the noninvasive evaluation of the venous system in patients with advanced chronic venous disease if duplex scanning does not provide definitive information on pathophysiology (CEAP class C ₃ -C ₆).	1	B
	4. Imaging studies		

Continued.

<i>Guideline No.</i>	<i>Guideline title</i>	<i>GRADE of recommendation</i>	<i>Level of evidence</i>
4.1	We recommend that in patients with varicose veins and more advanced chronic venous disease, computed tomography venography, magnetic resonance venography, ascending and descending contrast venography, and intravascular ultrasonography are used selectively, including but not limited to post-thrombotic syndrome, thrombotic or nonthrombotic iliac vein obstruction (May-Thurner syndrome), pelvic congestion syndrome, nutcracker syndrome, vascular malformations, venous trauma, tumors, and planned open or endovascular venous interventions.	1	B
	5. Laboratory evaluation		
5.1	We recommend that in patients with varicose veins, evaluation for thrombophilia is needed selectively for those with recurrent deep venous thrombosis, thrombosis at a young age, or thrombosis in an unusual site. Laboratory examinations are needed in patients with long-standing venous stasis ulcers and in selected patients who undergo general anesthesia for the treatment of chronic venous disease.	1	B
	6. Classification		
6.1	We recommend that the CEAP classification be used for patients with chronic venous disease. The basic CEAP classification is used for clinical practice, and the full CEAP classification system is used for clinical research.	1	A
6.2	We recommend that primary venous disorders, including simple varicose veins, be differentiated from secondary venous insufficiency and from congenital venous disorders because the three conditions differ in pathophysiology and management.	1	B
	7. Outcome assessment		
7.1	We recommend that the revised Venous Clinical Severity Score is used for assessment of clinical outcome after therapy for varicose veins and more advanced chronic venous disease.	1	B
7.2	We recommend that a quality-of-life assessment is performed with a disease-specific instrument to evaluate patient-reported outcome and the severity of chronic venous disease.	1	B
7.3	We recommend duplex scanning for follow-up of patients after venous procedures who have symptoms or recurrence of varicose veins.	1	B
7.4	We recommend reporting procedure-related minor and major complications after therapy.	1	B
	8. Medical therapy		
8.1	We suggest venoactive drugs (diosmin, hesperidin, rutosides, sulodexide, micronized purified flavonoid fraction, or horse chestnut seed extract [aescin]) in addition to compression for patients with pain and swelling due to chronic venous disease, in countries where these drugs are available.	2	B
8.2	We suggest using pentoxifylline or micronized purified flavonoid fraction, if available, in combination with compression, to accelerate healing of venous ulcers.	2	B
	9. Compression therapy		
9.1	We suggest compression therapy using moderate pressure (20 to 30 mm Hg) for patients with symptomatic varicose veins.	2	C
9.2	We recommend against compression therapy as the primary treatment of symptomatic varicose veins in patients who are candidates for saphenous vein ablation.	1	B
9.3	We recommend compression as the primary therapeutic modality for healing venous ulcers.	1	B
9.4	We recommend compression as an adjuvant treatment to superficial vein ablation for the prevention of ulcer recurrence.	1	A
	10. Open venous surgery		
10.1	For treatment of the incompetent great saphenous vein, we suggest high ligation and inversion stripping of the saphenous vein to the level of the knee.	2	B
10.2	To reduce hematoma formation, pain, and swelling, we recommend postoperative compression. The recommended period of compression in C ₂ patients is 1 week.	1	B

Continued.

<i>Guideline No.</i>	<i>Guideline title</i>	<i>GRADE of recommendation</i>	<i>Level of evidence</i>
10.3	For treatment of small saphenous vein incompetence, we recommend high ligation of the vein at the knee crease, about 3 to 5 cm distal to the saphenopopliteal junction, with selective invagination stripping of the incompetent portion of the vein.	1	B
10.4	To decrease recurrence of venous ulcers, we recommend ablation of the incompetent superficial veins in addition to compression therapy.	1	A
10.5	We suggest preservation of the saphenous vein using the ambulatory conservative hemodynamic treatment of varicose veins (CHIVA) technique only selectively in patients with varicose veins, when performed by trained venous interventionists.	2	B
10.6	We suggest preservation of the saphenous vein using the ambulatory selective varicose vein ablation under local anesthesia (ASVAL) procedure only selectively in patients with varicose veins.	2	C
10.7	We recommend ambulatory phlebectomy for treatment of varicose veins, performed with saphenous vein ablation, either during the same procedure or at a later stage. If general anesthesia is required for phlebectomy, we suggest concomitant saphenous ablation.	1	B
10.8	We suggest transilluminated powered phlebectomy using lower oscillation speeds and extended tumescence as an alternative to traditional phlebectomy for extensive varicose veins.	2	C
10.9	For treatment of recurrent varicose veins, we suggest ligation of the saphenous stump, ambulatory phlebectomy, sclerotherapy, or endovenous thermal ablation, depending on the etiology, source, location, and extent of varicosity.	2	C
	11. Endovenous thermal ablation		
11.1	Endovenous thermal ablations (laser and radiofrequency ablations) are safe and effective, and we recommend them for treatment of saphenous incompetence.	1	B
11.2	Because of reduced convalescence and less pain and morbidity, we recommend endovenous thermal ablation of the incompetent saphenous vein over open surgery.	1	B
	12. Sclerotherapy of varicose veins		
12.1	We recommend liquid or foam sclerotherapy for telangiectasia, reticular veins, and varicose veins.	1	B
12.2	For treatment of the incompetent saphenous vein, we recommend endovenous thermal ablation over chemical ablation with foam.	1	B
	13. Treatment of perforating veins		
13.1	We recommend against selective treatment of incompetent perforating veins in patients with simple varicose veins (CEAP class C ₂).	1	B
13.2	We suggest treatment of “pathologic” perforating veins that includes those with an outward flow duration of ≥500 ms, with a diameter of ≥3.5 mm, located beneath a healed or open venous ulcer (CEAP class C ₅ -C ₆).	2	B
13.3	For treatment of “pathologic” perforating veins, we suggest subfascial endoscopic perforating vein surgery, ultrasonographically guided sclerotherapy, or thermal ablations.	2	C
	14. Treatment of pelvic varicose veins		
14.1	We recommend noninvasive imaging with transabdominal and/or transvaginal ultrasonography, computed tomography, or magnetic resonance venography in selected patients with symptoms of pelvic congestion syndrome or symptomatic varices in the distribution of the pubis, labia, perineum, or buttocks.	1	C
14.2	We recommend retrograde ovarian and internal iliac venography in patients with pelvic venous disease, confirmed or suspected by noninvasive imaging studies, in whom an intervention is planned.	1	C
14.3	We suggest treatment of pelvic congestion syndrome and pelvic varices with coil embolization, plugs, or transcatheter sclerotherapy, used alone or together.	2	B
14.4	If less invasive treatment is not available or has failed, we suggest surgical ligation and excision of ovarian veins to treat reflux.	2	B

INTRODUCTION

In the United States, an estimated 23% of adults have varicose veins, and 6% have more advanced chronic venous disease (CVD), including skin changes and healed or active venous ulcers.¹ Varicose veins have long been considered a cosmetic problem that only affected emotional well-being but were not the source of disability. Varicosities, however, are frequently the cause of discomfort, pain, loss of working days, disability, and deterioration of health-related quality of life (QOL).¹⁻³ Severe CVD may also lead to loss of limb or loss of life.⁴

Evaluation of varicose veins has greatly progressed in the past 2 decades with the widespread availability of duplex ultrasonography.⁵ The treatment of varicose veins has also undergone dramatic changes with the introduction of percutaneous endovenous ablation techniques, including endovenous laser therapy (EVLA),^{6,7} radiofrequency ablation (RFA),⁸ and liquid or foam sclerotherapy.^{9,10} Open surgical treatment with stripping of the varicose veins performed under general anesthesia, with the associated pain, potential for wound complications, and loss of working days, has been largely replaced by percutaneous office-based procedures that can be performed under local or tumescent anesthesia with similar early and midterm results but with less discomfort to the patient, improved early QOL, and earlier return to work.¹¹⁻¹³

The purpose of this document is to report recently formulated current recommendations for the evaluation and treatment of patients with varicose veins of the lower limbs and pelvis. These *Guidelines* also include recommendations for management of superficial and perforating vein incompetence in patients with associated, more advanced CVDs, such as venous edema, skin changes, or ulcerations. To accomplish this task, a joint Venous Guideline Committee of the Society for Vascular Surgery (SVS) and the American Venous Forum (AVF) was established.

Under no circumstance should these *Guidelines* be construed in practice or legal terms as defining the “standard of care,” which is solely determined by the condition of the individual patient, treatment setting, and other factors. Individual factors in a given patient, such as symptom variance or combinations, comorbidities, work, and socioeconomic factors may dictate a different approach than that described in the *Guidelines*. Because technology and disease knowledge is rapidly expanding, new approaches may supersede these recommendations. As important new information on management of varicose veins and related CVD becomes available, these recommendations will be revised without delay.

METHODOLOGY OF GUIDELINES

Evidence-based medicine is the conscientious, explicit, and judicious use of the current best evidence in making decisions about the care of individual patients.¹⁴ Guidelines for the care of patients with varicose veins, as recommended in this report, are based on scientific evidence. The need for adopting evidence-based guidelines and reporting stan-

dards for venous diseases has long been recognized by international experts¹⁵ and by leaders of the SVS¹⁶ and AVF.¹⁷⁻²⁰ To define current guidelines, members of the Venous Guideline Committee reviewed the relevant literature, including previously published consensus documents and guidelines,²¹⁻³¹ meta-analyses,^{6-12,32-42} the AVF reports on the Venous Summit at the 2006 and 2009 Pacific Vascular Symposia^{13,43-46} and considered the recommendations published in the third edition of the *Handbook of Venous Disorders, Guidelines of the American Venous Forum*.⁴⁷

The guidelines in this publication are based on the Grading of Recommendations Assessment, Development, and Evaluation (GRADE) system, as it was described by Guyatt et al (Table I).⁴⁸ For each guideline, the letter A, B, or C marks the level of current evidence. The grade of recommendation of a guideline can be strong (1) or weak (2), depending on the risk and burden of a particular diagnostic test or a therapeutic procedure to the patient vs the expected benefit. The words “we recommend” are used for GRADE 1—strong recommendations—if the benefits clearly outweigh risks and burdens, or vice versa; the words “we suggest” are used for GRADE 2—weak recommendations—when the benefits are closely balanced with risks and burdens.

DEFINITIONS

In this document, the updated terminology for superficial, perforating, and deep veins of the leg and pelvis are used.^{49,50} Definitions of varicose and spider veins as well as other manifestations of CVD follow recommendations of the CEAP classification and the recent update on venous terminology of the International Committee of the AVF.^{51,52}

Varicose veins of the lower limbs are dilated subcutaneous veins that are ≥ 3 mm in diameter measured in the upright position.⁵³ Synonyms include varix, varices, and varicosities. Varicosity can involve the main axial superficial veins—the great saphenous vein (GSV) or the small saphenous vein (SSV)—or any other superficial vein tributaries of the lower limbs.

Most varicose veins are due to primary venous disease. The most frequent cause is likely an intrinsic morphologic or biochemical abnormality in the vein wall, although the etiology can also be multifactorial. Labropoulos et al⁵⁴ proposed that the origin of venous reflux in patients with primary varicose veins can be local or multifocal structural weakness of the vein wall and that this can occur together or independently of proximal saphenous vein valvular incompetence. Varicosities can also develop as a result of secondary causes, such as previous deep vein thrombosis (DVT), deep venous obstruction, superficial thrombophlebitis, or arteriovenous fistula. Varicose veins may also be congenital and present as a venous malformation.

Varicosities are manifestations of CVD.^{51,52} CVD includes various medical conditions of long duration, all involving morphologic and functional abnormalities of the venous system manifested by symptoms or signs (or both),

Table I. Grading recommendations according to evidence^a

<i>Grade</i>	<i>Description of recommendation</i>	<i>Benefit vs risk and burdens</i>	<i>Methodologic quality of supporting evidence</i>	<i>Implications</i>
1A	Strong recommendation, high-quality evidence	Benefits clearly outweigh risk and burdens, or vice versa	RCTs without important limitations or overwhelming evidence from observational studies	Strong recommendation, can apply to most patients in most circumstances without reservation
1B	Strong recommendation, moderate quality evidence	Benefits clearly outweigh risk and burdens, or vice versa	RCTs with important limitations (inconsistent results, methodologic flaws, indirect, or imprecise) or exceptionally strong evidence from observational studies	Strong recommendation, can apply to most patients in most circumstances without reservation
1C	Strong recommendation, low-quality or very low-quality evidence	Benefits clearly outweigh risk and burdens, or vice versa	Observational studies or case series	Strong recommendation but may change when higher quality evidence becomes available
2A	Weak recommendation, high-quality evidence	Benefits closely balanced with risks and burden	RCTs without important limitations or overwhelming evidence from observational studies	Weak recommendation, best action may differ depending on circumstances or patients' or societal values
2B	Weak recommendation, moderate-quality evidence	Benefits closely balanced with risks and burden	RCTs with important limitations (inconsistent results, methodologic flaws, indirect, or imprecise) or exceptionally strong evidence from observational studies	Weak recommendation, best action may differ depending on circumstances or patients' or societal values
2C	Weak recommendation, low-quality or very low-quality evidence	Uncertainty in the estimates of benefits, risks, and burden; benefits, risk, and burden may be closely balanced	Observational studies or case series	Very weak recommendations; other alternatives may be equally reasonable

RCT, Randomized controlled trial.

^aAdapted from Guyatt et al.⁴⁸ Used with permission.

indicating the need for investigation and care. The term *chronic venous disorder* is reserved for the full spectrum of venous abnormalities and includes dilated intradermal veins and venules between 1 and 3 mm in diameter (spider veins, reticular veins, telangiectasia; CEAP class C₁).

Varicose veins can progress to a more advanced form of chronic venous dysfunction such as chronic venous insufficiency (CVI).^{55,56} In CVI, increased ambulatory venous hypertension initiates a series of changes in the subcutaneous tissue and the skin: activation of the endothelial cells, extravasation of macromolecules and red blood cells, diapedesis of leukocytes, tissue edema, and chronic inflammatory changes most frequently noted at and above the ankles.^{41,53} Limb swelling, pigmentation, lipodermatosclerosis, eczema, or venous ulcerations can develop in these patients.

THE SCOPE OF THE PROBLEM

In the adult Western population, the prevalence of varicose veins is >20% (range, 21.8%-29.4%), and about 5% (range, 3.6%-8.6%) have venous edema, skin changes or venous ulcerations. Active venous ulcers are present in up to 0.5%, and between 0.6% and 1.4% have healed ulcers.⁵⁷ On the basis of estimates of the San Diego epidemiologic study, more than 11 million men and 22 million women between the ages of 40 and 80 years in the United States have varicose veins, and >2 million adults have advanced

CVD, with skin changes or ulcers.¹ The incidence of post-thrombotic venous ulcers has not changed in the past 2 decades for women, and it recently increased in men.⁵⁸ In the United States each year, at least 20,556 patients receive a new diagnosis of venous ulcers.³

The Bonn Vein Study,⁵⁹ which enrolled 3072 randomly selected participants (1722 women and 1350 men), aged from 18 to 79 years, found symptoms of CVD in 49.1% of men and in 62.1% of women. Also reported were varicose veins without edema or skin changes in 14.3% (12.4% men, 15.8% women), edema in 13.4% (11.6% men, 14.9% women), skin changes in 2.9% (3.1% men, 2.7% women), and healed or active ulceration in 0.6% or 0.1%, respectively. A French cross-sectional survey found varicose veins in 23.7% of men and 46.3% of women.⁶⁰

The National Venous Screening Program, under the auspices of the AVF, screened 2234 Americans for venous disease.⁶¹ The participants' mean age was 60 years, 77% were women, and 80% were white. The CEAP clinical classification of C₀ to C₆ was 29%, 29%, 23%, 10%, 9%, 1.5%, and 0.5%, respectively. Reflux or obstruction was noted in 37% and 5% of participants, respectively.

Progression of primary varicosity to severe CVI and venous ulcer is not rare: in the North American subfascial endoscopic perforator surgery (SEPS) registry, more patients with advanced CVI had primary venous disease than post-thrombotic syndrome (70% vs 30%).⁶² Bauer⁶³ had

already observed in 1948 that 58% of his patients with advanced CVD, studied with phlebography, never had a previous DVT.

Varicose veins and venous ulcers can be a great financial burden to patients and to society. Varicose veins and associated complications may lead to chronic pain, disability, decreased quality of life (QOL), loss of working days, and early retirement. In the United States, the direct medical cost of CVD has been estimated to be between \$150 million and \$1 billion annually.^{3,4} In the United Kingdom, 2% of the national health care budget per year (US \$1 billion) is spent on the management of leg ulcers.¹

Venous ulcer is an under-recognized and undertreated disease. A recently published supplement of the *Journal of Vascular Surgery* details the noble goal of the Pacific Vascular Symposium 6 (PVS6) to lead a call to action to formulate a doable and achievable plan to reduce the incidence of venous ulcers in the United States by 50% in 10 years.⁶⁴

ANATOMY

During the past decade, new venous terminology has been developed and adopted by vascular societies around the world.^{47,49,61} The success of assigning uniform names to common veins was accompanied by new information on anatomy obtained with duplex ultrasonography, three-dimensional computed tomography (CT), and magnetic resonance (MR) imaging; all these resulted in better understanding of the anatomy of veins and the pathology of CVD.^{33,62}

Superficial veins

Superficial veins of the lower limbs are those located between the deep fascia, covering the muscles of the limb, and the skin. The main superficial veins are the GSV and the SSV. All previous names used to describe these vessels (greater, long, lesser) should be abandoned. The GSV originates from the medial superficial veins of the dorsum of the foot and ascends in front of the medial malleolus along the medial border of the tibia, next to the saphenous nerve (Fig 1). There are posterior and anterior accessory saphenous veins in the calf and the thigh. The saphenofemoral junction (SFJ) is the confluence of superficial inguinal veins, comprising the GSV and the superficial circumflex iliac, superficial epigastric, and external pudendal veins. The GSV in the thigh lies in the saphenous subcompartment of the superficial compartment, between the saphenous fascia and the deep fascia.

The SSV is the most important posterior superficial vein of the leg (Fig 2). It originates from the lateral side of the foot and drains blood into the popliteal vein, joining it usually just proximal to the knee crease. The intersaphenous vein (vein of Giacomini), which runs in the posterior thigh, connects the SSV with the GSV.⁶⁵

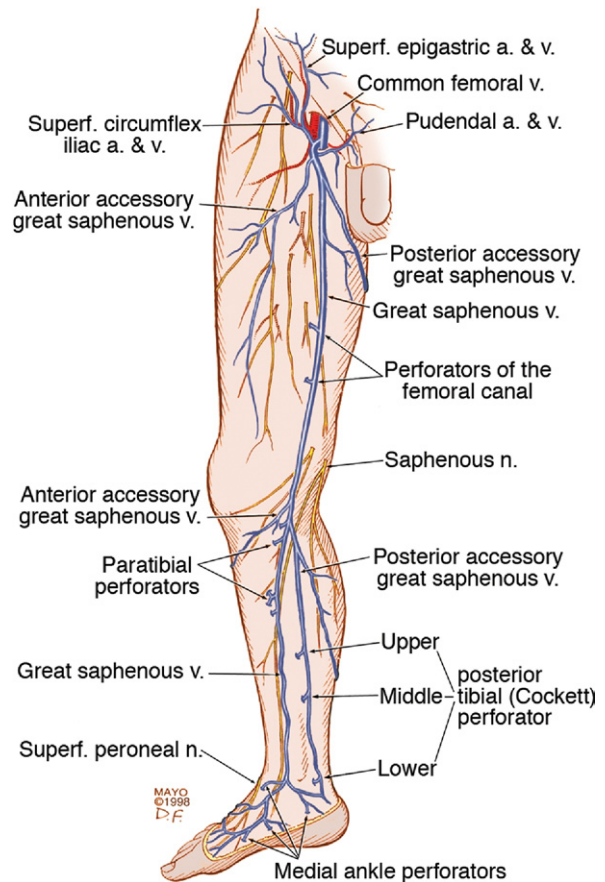


Fig 1. Medial superficial and perforating veins of the lower limb. (Used with permission of Mayo Foundation for Medical Education and Research.)

Deep veins

Deep veins accompany the main arteries of the limb and pelvis. The deep veins of the calf (anterior, posterior tibial, and peroneal veins) are paired structures, and the popliteal and femoral veins may also be paired. The gastrocnemius and soleal veins are important deep tributaries. The old term *superficial femoral vein* has been replaced by the new term *femoral vein*.⁵² The femoral vein connects the popliteal to the common femoral vein.

The pelvic veins include the external, internal, and common iliac veins, which drain into the inferior vena cava (IVC). Large gonadal veins drain into the IVC on the right and the left renal vein on the left.

Perforating veins

Perforating veins connect the superficial to the deep venous system (Fig 1). They pass through the deep fascia that separates the superficial compartment from the deep. Communicating veins connect veins within the same system. The most important leg perforating veins are the medial calf perforators.⁶⁶ The posterior tibial perforating veins (Cockett perforators in the old nomenclature) con-

Fig 2. Posterior superficial and perforating veins of the leg. (Used with permission of Mayo Foundation for Medical Education and Research.)

nect the posterior accessory GSV of the calf (the posterior arch vein in the old nomenclature) with the posterior tibial veins and form the lower, middle, and upper groups. They are located just behind the medial malleolus (lower), at 7 to 9 cm (middle) and at 10 to 12 cm (upper) from the lower edge of the malleolus. The distance between these perforators and the medial edge of the tibia is 2 to 4 cm.⁶⁶ (Fig 1). Paratibial perforators connect the main GSV trunk with the posterior tibial veins. In the distal thigh, perforators of the femoral canal usually connect directly the GSV to the femoral vein.

Venous valves

Bicuspid venous valves are important structures assisting unidirectional flow in the normal venous system. The GSV usually has at least 6 valves (range, 4-25), with a constant valve present within 2 to 3 cm of the SFJ in 85% of cases,⁶⁷ and the SSV has a median of 7 to 10 valves (range, 4-13).⁶⁸ There are valves in the deep veins of the lower limb, but the common femoral or external iliac vein has only one valve in about 63% of cases.⁶⁸ In 37%, there is no valve in the common femoral or external iliac veins. The internal iliac vein has a valve in 10%; its tributaries have valves in 9%.⁶⁹

DIAGNOSTIC EVALUATION

Clinical examination

Patients with varicose veins may present with no symptoms at all; the varices are then of cosmetic concern only, with an underlying psychologic impact. Psychologic concerns related to the cosmetic appearance of varicose veins will, however, reduce a patient's QOL in many cases.

Symptoms related to varicose veins or more advanced CVD include tingling, aching, burning, pain, muscle cramps, swelling, sensations of throbbing or heaviness, itching skin, restless legs, leg tiredness, and fatigue.⁷⁰ Although not pathognomonic, these symptoms suggest CVD, particularly if they are exacerbated by heat or dependency noted during the course of the day and relieved by resting or elevating the legs or by wearing elastic stockings or bandages.⁵¹ Pain during and after exercise that is relieved with rest and leg elevation (venous claudication) can also be caused by venous outflow obstruction caused by previous DVT or by narrowing or obstruction of the common iliac veins (May-Thurner syndrome).⁶⁹⁻⁷¹ Diffuse pain is more frequently associated with axial venous reflux, whereas poor venous circulation in bulging varicose veins usually causes local pain.

History. A thorough medical history is essential in the patient's evaluation and may establish the diagnosis of primary, secondary, or congenital varicosities. Questions to patients who present with varicose veins should address previous DVT or thrombophlebitis, established thrombophilia, medication history (particularly birth control pills), smoking, pregnancies, and a family history of varicosity or thrombotic disorders. Premenopausal women with varicose veins should also be questioned for symptoms of pelvic congestion syndrome (pelvic pain, aching, or heaviness; dyspareunia). Advanced age is the most important risk factor for varicose veins and for CVI. A positive family history, female sex, and multiparity are also risk factors for varicose veins, and a positive family history and obesity are risk factors for CVI.⁵⁷

Physical examination. Clinical evaluation should focus on signs of venous disease, and examination in the standing patient in a warm room, with good light, should establish the size, location, and distribution of varicose veins. Inspection and palpation are essential parts of the examination, and auscultation (bruit) is particularly helpful in those with vascular malformation and arteriovenous fistula.⁷¹ Varicose dilations or venous aneurysms, palpable cord in the vein, tenderness, a thrill, bruit, or pulsatility should be recorded. In addition, the presence of spider veins or telangiectasia, limb swelling that is usually partially pitting or nonpitting, induration, pigmentation, lipodermatosclerosis, atrophie blanche, eczema, dermatitis, skin discoloration, increased skin temperature, and healed or active ulcers should be documented.

Ankle mobility should also be examined, because patients with advanced venous disease frequently have decreased mobility in the ankle joints. Sensory and motor functions of the limb and foot are assessed to help differen-

tiate from diabetic neuropathy or any underlying neurologic problem. An abdominal mass or lymphadenopathy may be a clue to venous compression and outflow obstruction.

Corona phlebectatica (ankle flare or malleolar flare) is a fan-shaped pattern of small intradermal veins located around the ankle or the dorsum of the foot. This is considered an early sign of advanced venous disease. The pattern of the varicose veins should be established, because perineal, vulvar, or groin varicosity can be a sign of iliac vein obstruction or internal iliac vein or gonadal vein incompetence causing pelvic congestion syndrome. Scrotal varicosity may be a sign of gonadal vein incompetence, left renal vein compression between the superior mesenteric artery and the aorta (nutcracker syndrome), or occasionally, even IVC lesions or renal carcinoma. Varicose veins of the upper thigh can be caused by inferior gluteal vein reflux.^{72,73}

Classic tourniquet tests for saphenous or perforator incompetence or deep venous occlusion (Trendelenburg test, Ochsner-Mahorner test, Perthes test)⁷¹ are rarely used today; they are mostly of historic interest and should be used in rare instances, when duplex scanning or Doppler studies are not available. Distal palpation and proximal percussion of the saphenous vein, however, are useful tests to suggest valvular incompetence.

Skin lesions, such as capillary malformations, tumors, onychomycosis, or excoriations, should be noted and a complete pulse examination performed to exclude underlying peripheral arterial disease. An aneurysmal saphenous vein can be misdiagnosed as a femoral hernia or vice versa. The presence of a longer limb, lateral varicosity noted soon after birth, and associated capillary malformations are tip-offs for congenital venous malformation (Klippel-Trénaunay syndrome),^{74,75} whereas edema of the dorsum of the foot, squaring of the toes, thick skin, and nonpitting edema are signs of chronic lymphedema. The physical examination can be complemented by a handheld Doppler examination, although the latter does not replace evaluation of the venous circulation with color duplex scanning.

The Guideline Committee recommends using the basic CEAP classification^{76,77} (see *Classification of chronic venous disorders* later in the *Guidelines*) to document the clinical class, etiology, anatomy, and pathophysiology (CEAP) of CVD (Tables II and III). We also recommend use of the revised Venous Clinical Severity Score (VCSS)⁷⁸ to grade the severity of CVD (see *Outcome assessment*; Table IV).

The aim of the clinical evaluation is not only to determine the presenting signs and symptoms and the type of venous disease (primary, secondary, congenital) but also to exclude other etiologies, including peripheral arterial disease, rheumatoid disease, infection, tumor, or allergies. The physician should also establish the degree of disability caused by the venous disease and its impact on the patient's QOL.

Table II. The CEAP classification

CEAP	Description
1. Clinical classification	
C ₀	No visible or palpable signs of venous disease
C ₁	Telangiectases or reticular veins
C ₂	Varicose veins
C ₃	Edema
C _{4a}	Pigmentation and/or eczema
C _{4b}	Lipodermatosclerosis and/or atrophic blanche
C ₅	Healed venous ulcer
C ₆	Active venous ulcer
C _S	Symptoms, including ache, pain, tightness, skin irritation, heaviness, muscle cramps, as well as other complaints attributable to venous dysfunction
C _A	Asymptomatic
2. Etiologic classification	
E _c	Congenital
E _p	Primary
E _s	Secondary (postthrombotic)
E _n	No venous etiology identified
3. Anatomic classification	
A _s	Superficial veins
A _p	Perforator veins
A _d	Deep veins
A _n	No venous location identified
4. Pathophysiologic classification	
P _r	Reflux
P _o	Obstruction
P _{r,o}	Reflux and obstruction
P _n	No venous pathophysiology identifiable

Adapted from Eklöf et al.⁷⁷ Used with permission.

Duplex scanning

Duplex scanning is recommended as the first diagnostic test for all patients with suspected CVD.^{5,79} The test is safe, noninvasive, cost-effective, and reliable. It has much better diagnostic accuracy in the assessment of venous insufficiency than continuous-wave Doppler ultrasonography.⁸⁰ B-mode imaging permits accurate placement of the pulsed Doppler sample volume, and the addition of color makes it easier to establish obstruction, turbulence, and the direction of venous and arterial flow.⁴⁴ Duplex scanning is excellent for the evaluation of infrainguinal venous obstruction and valvular incompetence.⁸¹ It also differentiates between acute venous thrombosis and chronic venous changes.^{82,83}

Technique of the examination. The technique of venous duplex scanning has been described in detail previously by several authors.^{80,83-88} The pulsed-wave Doppler of 4 to 7-MHz linear array transducers are used most frequently for the deeper veins, with the higher-frequency probes used more to assess the superficial veins. Evaluation of reflux in the deep and superficial veins with duplex scanning should be performed with the patient upright,

Table III. Venous anatomic segment classification

Superficial veins	
1.	Telangiectases/reticular veins
2.	GSV above knee
3.	GSV below knee
4.	Short saphenous vein
5.	Nonsaphenous veins
Deep veins	
6.	Inferior vena cava
7.	Common iliac vein
8.	Internal iliac vein
9.	External iliac vein
10.	Pelvic: gonadal, broad ligament veins, other
11.	Common femoral vein
12.	Deep femoral vein
13.	Femoral vein
14.	Popliteal vein
15.	Crural veins: anterior tibial, posterior tibial, peroneal veins (all paired)
16.	Muscular veins: gastrocnemius, soleal, other
Perforating veins	
17.	Thigh perforator veins
18.	Calf perforator veins

Adapted from Eklöf et al.⁷⁷ Used with permission.

with the leg rotated outward, heel on the ground, and weight taken on the opposite limb.⁵ The supine position gives both false-positive and false-negative results of reflux.⁸⁴

The examination is started below the inguinal ligament, and the veins are examined in 3- to 5-cm intervals. For a complete examination, all deep veins of the leg are examined, including the common femoral, femoral, deep femoral, popliteal, peroneal, soleal, gastrocnemial, anterior, and posterior tibial veins. The superficial veins are then evaluated, including the GSV, the SSV, the accessory saphenous veins, and the perforating veins.

The four components that should be included in a complete duplex scanning examination for CVD are (1) visibility, (2) compressibility, (3) venous flow, including measurement of the duration of reflux, and (4) augmentation. Asymmetry in flow velocity, lack of respiratory variations in venous flow, and waveform patterns at rest and during flow augmentation in the common femoral veins indicate proximal obstruction. Reflux can be elicited in two ways: increased intra-abdominal pressure using a Valsalva maneuver for the common femoral vein or the SFJ, or by manual compression and release of the limb distal to the point of examination. The first is more appropriate for evaluation of reflux in the common femoral vein and at the SFJ, whereas compression and release is the preferred technique more distally on the limb.⁸⁴ The advantage of a distal cuff deflation was emphasized by van Bemmelen et al.⁸⁵

The cutoff value for abnormally reversed venous flow (reflux) in the saphenous, tibial, and deep femoral veins has been 500 ms.⁸¹ International consensus documents previously recommended 0.5 seconds as a cutoff value for all veins to use for lower limb venous incompetence.^{5,22,86} This value is, however, longer, 1 second, for the femoral and popliteal veins.⁸¹ For the perforating veins, cutoff

values of both 350 ms and 500 ms have been suggested.^{5,81} The Committee recommends 500 ms as the cutoff value for saphenous, tibial, deep femoral, and perforating vein incompetence, and 1 second for femoral and popliteal vein incompetence.

Perforating veins have been evaluated in patients with advanced disease, usually in those with healed or active venous ulcers (CEAP class C₅-C₆) or in those with recurrent varicose veins after previous interventions. The diameter of clinically relevant "pathologic" perforators (eg, beneath healed or open venous ulcer) may predict valve incompetence. In a study by Labrapoulos et al,⁸⁷ a perforator vein diameter >3.9 mm had a high specificity (96%) but a low sensitivity (73%) to predict incompetence, given that almost one-third of the incompetent perforators had a diameter of <3.9 mm.^{87,88} Sandri et al,⁸⁹ however, found that a perforator diameter of ≥3.5 mm was associated with reflux in >90% of cases. The SVS/AVF Guideline Committee definition of "pathologic" perforating veins includes those with outward flow of ≥500 ms, with a diameter of ≥3.5 mm, located beneath a healed or open venous ulcer (CEAP class C₅-C₆).^{5,81,88,89}

Duplex findings in CVD. A duplex evaluation of patients with CVD demonstrated that superficial vein reflux was present in 90% and that 70% to 80% have reflux in the GSV.⁹⁰ Patients with venous ulcers usually have multilevel disease affecting the superficial, deep, and perforating veins. Duplex evaluations have also revealed that 74% to 93% of all patients with venous ulcers have superficial vein incompetence, with superficial venous reflux being the only abnormality in 17% to 54% of the limbs. Of 239 patients with venous ulcers evaluated with duplex scanning in three different studies, 144 (60.3%) had incompetent perforating veins, and 141 (59%) had deep vein incompetence or obstruction.⁹¹⁻⁹³

Plethysmography

Plethysmography (air or strain-gauge) is used for the noninvasive evaluation of calf muscle pump function, global venous reflux, and venous outflow obstruction.^{86,94-96} Strain-gauge plethysmography is usually performed with a modified protocol of Struckmann, validated previously by comparison with simultaneously recorded ambulatory venous pressure measurements.⁹⁷⁻¹⁰⁰ Strain-gauge or air plethysmography consists of exercise venous plethysmography, measurement of passive refill and drainage, and outflow plethysmography. Plethysmography quantifies venous reflux and obstruction and has been used to monitor venous functional changes and assess physiologic outcome of surgical treatments.⁹⁵ For more details of these examinations, the reader is referred to original articles^{94,96,97} and a recent relevant book chapter.¹⁰⁰

The use of plethysmography is less frequently indicated in patients with CEAP C₂ disease (simple varicose veins), but these studies provide information on venous function in patients with CVI, and they are complementary examination to duplex scanning. Examples for use in patients may include those with suspected outflow obstruction but normal duplex findings or those suspected of having venous

Table IV. Revised Venous Clinical Severity Score

	<i>None: 0</i>	<i>Mild: 1</i>	<i>Moderate: 2</i>	<i>Severe: 3</i>
Pain or other discomfort (ie, aching, heaviness, fatigue, soreness, burning); presumes venous origin	None	Occasional pain or other discomfort (ie, not restricting regular daily activity)	Daily pain or other discomfort (ie, interfering with but not preventing regular daily activities)	Daily pain or discomfort (ie, limits most regular daily activities)
Varicose veins "Varicose" veins must be ≥ 3 mm in diameter to qualify in the standing position	None	Few: scattered (ie, isolated branch varicosities or clusters); also includes corona phlebectatica (ankle flare)	Confined to calf or thigh	Involves calf and thigh
Venous edema Presumes venous origin	None	Limited to foot and ankle area	Extends above ankle but below knee	Extends to knee and above
Skin pigmentation Presumes venous origin; does not include focal pigmentation over varicose veins or pigmentation due to other chronic diseases (ie, vasculitis purpura)	None or focal	Limited to perimalleolar area	Diffuse over lower third of calf	Wider distribution above lower third of calf
Inflammation More than just recent pigmentation (ie, erythema, cellulitis, venous eczema, dermatitis)	None	Limited to perimalleolar area	Diffuse over lower third of calf	Wider distribution above lower third of calf
Induration Presumes venous origin of secondary skin and subcutaneous changes (ie, chronic edema with fibrosis, hypodermatitis); includes white atrophy and lipodermatosclerosis	None	Limited to perimalleolar area	Diffuse over lower third of calf	Wider distribution above lower third of calf
No. of active ulcers	0	1	2	≥ 3
Active ulcer duration (longest active)	NA	<3 mo	>3 mo but <1 y	Not healed for >1 y
Active ulcer size (largest active)	NA	Diameter <2 cm	Diameter 2-6 cm	Diameter >6 cm
<i>Use of compression therapy</i>	<i>None: 0</i>	<i>Occasional: 1</i>	<i>Frequent: 2</i>	<i>Always: 3</i>
	Not used	Intermittent use of stockings	Wears stockings most days	Full compliance: stockings

Adapted from Vasquez et al.¹²³ Used with permission.

disease due to calf muscle pump dysfunction, but no reflux or obstruction was noted on duplex scanning. Air plethysmography remains one of the few noninvasive techniques that can quantify reflux reliably^{98,99} although other parameters have been reported to be variably useful. The Guideline Committee encourages using air plethysmography as "best practice" in the evaluation of patients with advanced CVD if duplex scanning does not provide definitive diagnosis on pathophysiology (CEAP C₃-C₆).

Imaging studies

Contrast venography. Ascending or descending contrast venography for varicosities or other forms of CVD is performed selectively in patients with deep venous obstruction,

in patients with post-thrombotic syndrome, and if endovenous or open surgical treatment is planned. It can be used with direct venous pressure measurements to evaluate patients with varicose veins and associated iliac vein obstruction (May-Thurner syndrome). Contrast venography is routinely used in CVD to perform endovenous procedures, such as angioplasty or venous stenting or open venous reconstructions.

CT and MR venography. Patients with simple varicose veins rarely require imaging studies more sophisticated than duplex ultrasonography. The techniques of CT and MR imaging have progressed tremendously in the past decade, and they provide excellent three-dimensional imaging of the venous system. MR and CT are both suitable

Guideline 1. Clinical examination

<i>Guideline No.</i>	<i>1. Clinical examination</i>	<i>GRADE of recommendation</i>	<i>Level of evidence</i>
		1. Strong	A. High quality
		2. Weak	B. Moderate quality C. Low or very low quality
1.1	For clinical examination of the lower limbs for chronic venous disease, we recommend inspection (telangiectasia, varicosity, edema, skin discoloration, corona phlebectatica, lipodermatosclerosis, ulcer), palpation (cord, varicosity, tenderness, induration, reflux, pulses, thrill, groin or abdominal masses) auscultation (bruit), and examination of ankle mobility. Patients should be asked for symptoms of chronic venous disease, which may include tingling, aching, burning, pain, muscle cramps, swelling, sensations of throbbing or heaviness, itching skin, restless legs, leg tiredness, and fatigue.	1	A

Guideline 2. Duplex scanning

<i>Guideline No.</i>	<i>2. Duplex scanning</i>	<i>GRADE of recommendation</i>	<i>Level of evidence</i>
		1. Strong	A. High quality
		2. Weak	B. Moderate quality C. Low or very low quality
2.1	We recommend that in patients with chronic venous disease, a complete history and detailed physical examination are complemented by duplex scanning of the deep and superficial veins. The test is safe, noninvasive, cost-effective, and reliable.	1	A
2.2	We recommend that the four components of a complete duplex scanning examination for chronic venous disease should be visualization, compressibility, venous flow, including measurement of duration of reflux, and augmentation.	1	A
2.3	We recommend that reflux to confirm valvular incompetence in the upright position of the patients be elicited in one of two ways: either with increased intra-abdominal pressure using a Valsalva maneuver to assess the common femoral vein and the saphenofemoral junction, or for the more distal veins, use of manual or cuff compression and release of the limb distal to the point of examination.	1	A
2.4	We recommend a cutoff value of 1 second for abnormally reversed flow (reflux) in the femoral and popliteal veins and of 500 ms for the great saphenous vein, the small saphenous vein, the tibial, deep femoral, and the perforating veins.	1	B
2.5	We recommend that in patients with chronic venous insufficiency, duplex scanning of the perforating veins is performed selectively. We recommend that the definition of "pathologic" perforating veins includes those with an outward flow of duration of ≥ 500 ms, with a diameter of ≥ 3.5 mm and a location beneath healed or open venous ulcers (CEAP class C ₅ -C ₆).	1	B

to identify pelvic venous obstruction or iliac vein stenosis in patients with lower limb varicosity when a proximal obstruction or iliac vein compression (May-Thurner syndrome) is suspected.¹⁰¹ They are suitable to establish left renal vein compression (nutcracker syndrome),¹⁰² gonadal vein incompetence, and pelvic venous congestion syndrome. MR imaging with gadolinium is especially useful in evaluating patients with vascular malformations, including those with congenital varicose veins.

Intravascular ultrasonography. Intravascular ultrasonography (IVUS) has been used successfully to evaluate iliac vein compression or obstruction and to monitor patients after venous stenting.¹⁰¹ For patients with varicose

veins, IVUS should be used selectively in those with suspected or confirmed iliac vein obstruction. IVUS is important in assessing the morphology of the vessel wall, identifying lesions such as trabeculations, frozen valves, mural thickness, and external compression that are not seen with conventional contrast venography, and it provides measurements in assessing the degree of stenosis. In addition, IVUS confirms the position of the stent in the venous segment and the resolution of the stenosis.¹⁰¹

Laboratory evaluation

Patients with varicose veins are usually operated on under local or tumescent anesthesia, and specific laboratory

Guideline 3. Plethysmography

<i>Guideline No.</i>	<i>3. Plethysmography</i>	<i>GRADE of recommendation</i>	<i>Level of evidence</i>
		1. Strong	A. High quality
		2. Weak	B. Moderate quality C. Low or very low quality
3.1	We suggest that venous plethysmography be used selectively for the noninvasive evaluation of the venous system in patients with simple varicose veins (CEAP class C ₂).	2	C
3.2	We recommend that venous plethysmography be used for the noninvasive evaluation of the venous system in patients with advanced chronic venous disease if duplex scanning does not provide definitive information on pathophysiology (CEAP class C ₃ -C ₆).	1	B

Guideline 4. Imaging studies

<i>Guideline No.</i>	<i>4. Imaging studies</i>	<i>GRADE of recommendation</i>	<i>Level of evidence</i>
		1. Strong	A. High quality
		2. Weak	B. Moderate quality C. Low or very low quality
4.1	We recommend that in patients with varicose veins and more advanced chronic venous disease, computed tomography venography, magnetic resonance venography, ascending and descending contrast venography, and intravascular ultrasonography are used selectively for indications, including but not limited to post-thrombotic syndrome, thrombotic or nonthrombotic iliac vein obstruction (May-Thurner syndrome), pelvic congestion syndrome, nutcracker syndrome, vascular malformations, venous trauma, tumors, and planned open or endovascular venous interventions.	1	B

tests are not routinely performed. In those with recurrent DVT, thrombosis at a young age, or thrombosis in an unusual site, we recommend screening for thrombophilia. Laboratory examination is also needed in patients with long-standing recalcitrant venous ulcers. One study found 2.1% of venous and arterial ulcers had a secondary etiology, including neoplasia, chronic inflammation, sickle cell disease, vasculitis, rheumatoid arthritis, pyoderma gangrenosum, and hydroxyurea.¹⁰³ Patients who undergo general anesthesia for treatment of CVD may need a blood cell count or an electrolyte panel.

CLASSIFICATION OF CVD

The cornerstone for management of CVD is the proper diagnosis and accurate classification of the underlying venous problem, which create the base for correctly directed treatment. The clinical and laboratory evaluation of the patient with varicose veins or more advanced CVD should be completed by establishing the clinical class of the disease. The CEAP classification was developed by the AVF in 1994 and later revised in 2004.^{76,77} The classification is based on

clinical signs of venous disease (C), etiology (E), anatomy (A), and the underlying pathophysiology (P).

Clinical class includes the full spectrum of venous disorders, from no signs of visible venous disease (C₀) to telangiectasia or reticular veins (C₁), varicose veins (C₂), edema (C₃), skin changes, such as pigmentation or eczema (C_{4a}) or lipodermatosclerosis or atrophie blanche (C_{4b}), and healed (C₅) or active (C₆) ulcer. The presence or absence of symptoms is also recorded as S (symptomatic) or A (asymptomatic).

Etiology can be congenital (E_c), primary (E_p), or secondary (E_s).

The anatomic classification separates superficial venous disease (A_s) from involvement of the perforators (A_p) or deep veins (A_d). Failure to identify an anatomic location is also coded (A_n).

Pathophysiology of the disease can be reflux (P_r), obstruction (P_o), or both. Failure to identify venous pathophysiology is also noted (P_n). Table II includes the full CEAP classification, and Table III lists the venous segments that can be involved in the disease.

Guideline 5. Laboratory evaluation

<i>Guideline No.</i>	<i>5. Laboratory evaluation</i>	<i>GRADE of recommendation</i>	<i>Level of evidence</i>
		1. Strong	A. High quality
		2. Weak	B. Moderate quality C. Low or very low quality
5.1	We recommend that in patients with chronic venous disease, evaluation for thrombophilia is needed selectively for those with recurrent deep vein thrombosis, thrombosis at a young age, or thrombosis in an unusual site. Laboratory examination is needed in patients with long-standing venous stasis ulcers (blood cell count and metabolic panel) and in selected patients who undergo general anesthesia for the treatment of chronic venous disease.	1	B

Guideline 6. Classification

<i>Guideline No.</i>	<i>6. Classification</i>	<i>GRADE of recommendation</i>	<i>Level of evidence</i>
		1. Strong	A. High quality
		2. Weak	B. Moderate quality C. Low or very low quality
6.1	We recommend that the CEAP classification be used for patients with varicose veins. The basic CEAP classification is used for clinical practice, and the full CEAP classification system is used for clinical research.	1	A
6.2	We recommend that primary venous disorders, including simple varicose veins, be differentiated from secondary venous insufficiency and from congenital venous disorders because the three conditions differ in pathophysiology and management.	1	B

The basic CEAP classification is a simplified version, suitable and easy for office use, and does not have the details of the comprehensive CEAP classification, which functions more as a research tool. As discussed in more detail by Meissner et al,¹³ for a patient with primary, symptomatic varicose veins and full saphenous and perforator incompetence (anatomic segments 2, 3, and 18 in Table III) with a small healed venous ulcer and skin pigmentation, the comprehensive CEAP classification would be C_{2,4a,5,S}E_pA_{s,p}P_{r2,3,18}.

Using the basic CEAP, the same patient would be classified as C_{5,S}E_pA_{s,p}P_r. In the basic CEAP classification, only the highest score is used to denote the clinical class and only the main anatomic groups (s, p, and d) are noted.

The revised format of the classification⁷⁷ includes two elements in addition to the C-E-A-P findings: the date of the examination and the level of the diagnostic evaluation:

Level 1: History, physical examination, Doppler examination (handheld)

Level 2: Noninvasive—duplex scan, plethysmography

Level 3: Invasive or complex evaluation—contrast venography, venous pressure measurements, IVUS, CT venography, MR venography

The accuracy of the diagnosis increases with the addition of imaging and invasive testing. Recording the date and method used to confirm the clinical impression can be added in parentheses after the CEAP recording as follows:

Full form: C_{2,4a,5,S}E_pA_{s,p}P_{r2,3,18} (Level 2, Feb 8, 2010)
Basic form: C_{5,S}E_pA_{s,p}P_r (Level 2; Feb 8, 2010)

The main purpose of using the CEAP classification in patients with CVD is to distinguish primary venous disease from congenital varicosity and, most importantly, from secondary, post-thrombotic venous insufficiency.⁵³ Evaluation and treatment of the three conditions are distinctly different.

OUTCOME ASSESSMENT

Outcome assessment of therapy of varicose veins and more advanced CVD includes standardized objective criteria that reflect patient symptoms, characteristic signs, and objective measures of functional and disease-specific QOL.¹⁰⁴

Generic QOL instruments

Generic QOL measures allow comparison with population norms and other disease states and provide a measure

of any ill effects of treatment. Generic and disease-specific QOL measures are usually complementary and should be used together. Of the generic QOL instruments the Short Form 36-Item Health Survey (SF-36) has been used with success for assessment of global well-being of patients with varicose veins.^{105,106}

Venous disease-specific QOL instruments

Disease-specific QOL measurements are sensitive to the beneficial effects of treatment. Different disease-specific, patient-generated QOL tools and patient-reported outcomes (PROs) have been popular in venous disease reporting.^{107,108} The most frequently used validated venous disease-specific instruments include the Venous Insufficiency Epidemiologic and Economic Study of Quality-of-Life (VEINES-QOL/Sym) questionnaire scale, the Chronic Venous Insufficiency Questionnaire (CIVIQ), the Aberdeen Varicose Vein Questionnaire (AVVQ), and the Charing Cross Venous Ulceration Questionnaire (CXVUQ).^{2,109-113}

The VEINES instrument consists of 35 items in two categories that generate two summary scores.¹⁰⁹ The VEINES-QOL questionnaire comprises 25 items that study the effect of disease on QOL, and the VEINES symptom questionnaire (VEINES-Sym) has 10 items that measure symptoms. The focus of VEINES is on physical symptoms rather than psychologic and social aspects.

The CIVIQ 2 is a revision of an instrument developed to measure physical, psychologic, social, and pain factors.¹¹³ The revised version gives equal weight to each category, with 20 questions that provide a global score.³ CIVIQ has been used in studies^{3,4} and proved to be a valid QOL measurement.

The AVVQ is a 13-question survey addressing all elements of varicose vein disease. Physical symptoms and social issues, including pain, ankle edema, ulcers, compression therapy use, and effect on daily activities, are examined in addition to cosmesis issues. The questionnaire is scored from 0 (no effect from varicose veins) to 100 (severe effect).^{114,115}

The CXVUQ was developed to provide a QOL measure for patients with venous ulcers. It provides a consistent measure of patient-reported QOL in venous ulcers regardless of the treatment selected. Combining it with a generic measurement instrument may provide valuable information on the progression of ulcers and on the available treatment measures.³

Physician-generated measurement tools

The physician-generated measurement tools include the CEAP classification,^{76,77} which, as discussed previously, is an accurate description of signs and symptoms. However, the instrument contains too many static elements, especially in classes C₄ and C₅, and is not particularly suitable for an assessment of improvement after therapy.¹¹⁶

The VCSS was introduced by Rutherford et al¹⁰⁴ and has been used successfully in several studies to evaluate

changes in signs and symptoms over time and to quantify outcomes.^{108,116-121} The VCSS is based on physician assessment of nine clinical signs or symptoms of CVD, including pain, presence of varicose veins, edema, signs of CVI, and venous ulcers. Compliance with compression therapy is also assessed. The VCSS correlates well with the CEAP score and with ultrasonographic assessment of the severity of venous valvular incompetence or obstruction.^{113,121-126}

A revised VCSS (Table IV) has been developed recently to clarify ambiguities, update terminology, and simplify application of the first version.⁷⁸ It now incorporates the important language of the PRO assessment tools. The presumption of venous origin is intended for all clinical descriptors, and each limb is considered and scored separately. These revisions are currently being validated in a multicenter field test.

The strength of the VCSS is in its evaluative properties in identifying subtle intrasubject changes over time after an intervention.^{122,123} An evaluation of each VCSS component allows outcome analysis on many levels, including technical, patient-reported, and clinical outcomes. In this sense, the revised VCSS is unique among clinical outcome assessments and PROs. Although it is administered by a physician, components such as pain are scored by patient responses to subjective questions.⁷⁸

To assess the benefit of a therapy, primary clinical outcome standards are usually combined with a secondary surrogate outcome assessment.¹²⁴ Recommended reporting standards and outcome assessment for endovenous ablation have recently been published in a joint statement of the AVF and the Society of Interventional Radiology.¹²⁴

Clinical outcomes. Clinical outcome studies evaluate the results of procedures on patient-focused outcomes, including symptom improvement, recurrence of varicosity, healing or recurrence of skin ulcers, improvement in the chronic, progressive symptoms of CVD, improved QOL, and cosmetic improvement.¹²⁴

Relief of symptoms. To report improvement in symptoms of CVD, we recommend the use of the revised VCSS in daily clinical practice.⁷⁸ For research and publications to report outcomes, one of the validated, disease-specific QOL instruments should be added, such as VEINES-QOL/Sym questionnaire scale, CIVIQ-2, the AVVQ, or the CXVUQ score in patients with advanced venous disease.^{2,3,109-113} A validated Likert pain scale can also be used, although most QOL questionnaires assess pain and discomfort.

Disease severity. We recommend using the basic CEAP clinical classification along with the revised VCSS in routine clinical practice. The revised VCSS is the best currently available instrument to quantify improvement and assess changes in the severity of CVD during follow-up (short-term, <1 year, midterm, 1-3 years, long term, >3 years; Table IV).¹⁰⁸ For research purposes, the complete CEAP classification should be used in addition to evaluation of QOL after treatment to help to assess the patient's perception of the burden of the disease. A general QOL

instrument, such as the SF-36, and one of the disease-specific QOL instruments (eg, VEINES, CIVIQ, Ab-erdeen) should both be used for this purpose.

Cosmetic results. Assessment of recurrent or residual varicose veins continues to be a challenge, and there are significant differences between physician assessments and patient-reported results. Patient satisfaction is directly related to the disappearance of the treated unsightly varicose veins. Photographing the treated areas is encouraged to assess late results on varicose vein recurrence and the status of skin changes. The Recurrent Varicose Veins After Surgery (REVAS) classification¹²⁵ is a descriptive evaluation of recurrent and residual varicosities based on the physician's assessment, and we suggest its use, although further modification of the assessment is warranted.

Surrogate outcomes

Surrogate outcomes assess specific technical questions about a particular therapy. Surrogate outcomes may include patency of the ablated saphenous or perforating vein, patency of a venous stent, or hemodynamic results after interventions. These should be used with care when evaluating the clinical benefit of an intervention.¹²⁴

Anatomic success. Patency of an ablated vein and the length of the patent or obstructed segment of the vein, as confirmed with duplex scanning, should be reported when assessing anatomic success. Postprocedural duplex scanning ≤ 1 month, at 1 year, at 1 to 3 years, and > 3 years is important to define periprocedural, early, midterm, and late failures. Timing of the study is important because saphenous patency after ablation on a periprocedural duplex image (< 3 days) indicates technical failure, whereas late patency after early occlusion suggests recanalization. The type of recurrence on late duplex scanning should also be documented, because recanalization of a previously occluded axial vein should be distinguished from neovascularization, which implies the presence of multiple small tortuous connections between the saphenous stump or the femoral vein and a residual saphenous vein or its tributaries.¹²⁴

Hemodynamic success. The presence or absence of recurrent reflux in treated incompetent veins should be documented by duplex scanning, because this represents technical failure or success of the procedure.¹²⁶ Changes in venous hemodynamics of the limb can also be documented by changes in plethysmographic findings before and after therapy; hemodynamic results frequently correlate with clinical outcome.^{95,127}

Safety

The safety of any procedure used for treatment of varicose veins or more advanced CVD needs to be established, and the procedurally related early adverse effects (< 30 days) and late complications should be documented. Table V defines minor and major complications for reporting purposes.¹²⁴

Table V. Definition of complications

Minor complications
No therapy, no consequence
Nominal therapy, no consequence; includes overnight admission for observation only
Major complications
Requires therapy, minor hospitalization (< 48 h)
Requires major therapy, unplanned increase in level of care, prolonged hospitalization (> 48 h)
Permanent adverse sequelae
Death

Adapted from Kundu et al.¹²⁴ Used with permission.

TREATMENT

Indications

Most patients who seek treatment for varicose veins have symptoms of aching, throbbing, feeling of a heavy leg, fatigue, cramps, pruritus, restless leg, ankle swelling, and tenderness or pain along bulging varicose veins. Some will have history of thrombophlebitis or bleeding from superficial varicose veins or have signs of more advanced CVD, such as edema, skin changes, including lipodermatosclerosis, eczema, pigmentation, atrophie blanche, corona phlebectatica, and healed or active ulceration. Less frequently, the veins are of cosmetic concern only.

Medical treatment

Venoactive drugs have been available for treatment of symptoms of varicose veins and more advanced forms of CVD for decades, and they have also been used to decrease ankle swelling and accelerate ulcer healing.¹²⁸ Many compounds have been tried with varying success, but the most promising drugs include saponins, such as the horse chestnut seed extract (aescin)¹²⁹; gamma-benzopyrenes (flavonoids), such as rutosides, diosmin, and hesperidin; the micronized purified flavonoid fraction (MPFF),¹³⁰ and other plant extracts such as French maritime pine bark extract. Synthetic products include calcium dobesilate, naf-tazone, and benzarone.¹³¹

The principle for the use of venoactive drugs has been to improve venous tone and capillary permeability, although a precise mechanism of action of most of these drugs is unknown. Flavonoids appear to affect leukocytes and the endothelium by modifying the degree of inflammation and reducing edema.⁵⁶

A recent Cochrane review of 110 publications selected 44 well-documented studies for analysis.¹³² The meta-analysis found that there appeared to be an effect on edema and on restless leg syndrome. Diosmin, hesperidin, and MPFF have been the most effective venoactive drugs. Calcium dobesilate reduced cramps and restless legs. Diosmin and hesperidin helped healing of trophic skin changes and were useful in treatment of cramps and swelling. Rutosides decreased venous edema. This meta-analysis, however, concluded that there is insufficient evidence to support the global use of venoactive drugs in the treatment of CVD.¹³²

Guideline 7. Outcome assessment

<i>Guideline No.</i>	<i>7. Outcome assessment</i>	<i>GRADE of recommendation</i>	<i>Level of evidence</i>
		1. Strong	A. High quality
		2. Weak	B. Moderate quality C. Low or very low quality
7.1	We recommend that the revised Venous Clinical Severity Score is used for assessment of clinical outcome after therapy for varicose veins and more advanced chronic venous disease.	1	B
7.2	We recommend that quality-of-life assessment is performed with a disease-specific instrument to evaluate patient-reported outcome and the severity of chronic venous disease.	1	B
7.3	We recommend duplex scanning for follow-up of patients after venous procedures who have symptoms or recurrence of varicose veins.	1	B
7.4	We recommend reporting procedure-related minor and major complications after therapy.	1	B

Horse chestnut seed extract. A separate Cochrane review of 17 randomized controlled trials (RCTs) found that horse chestnut seed extract (aescin) was effective to decrease edema, pain, and itching.¹²⁹

Pentoxifylline. The effect of pentoxifylline on ulcer healing was investigated in an RCT by Dale et al.¹³³ In a double-blind, placebo-controlled trial, complete healing of venous ulcers was observed in 64% of patients receiving pentoxifylline and in 53% of the patients receiving placebo. However, the difference was not statistically significant.

In another RCT, Falanga et al¹³⁴ investigated the effect of pentoxifylline on ulcer healing in 133 patients. Patients who were given 800 mg of pentoxifylline three times a day healed faster than those receiving placebo ($P = .043$). The median time to complete healing was 100, 83, and 71 days for placebo, pentoxifylline (400 mg), and pentoxifylline (800 mg) three times a day, respectively. A higher dose of pentoxifylline (800 mg three times a day) was more effective than the lower dose, although the higher dose had more significant gastrointestinal upset. The study concluded that pentoxifylline is effective in accelerating healing of leg ulcers.

In a more recent RCT, evidence to add pentoxifylline to a regimen of high-compression therapy to increase the chances of wound healing was of moderate quality.¹³⁵ Pentoxifylline increased the proportion of ulcer healing compared with placebo, although this finding was only statistically significant ($P = .046$) when a secondary adjusted analysis was conducted. Pentoxifylline in an oral dose of 400 mg three times daily is suggested to patients with venous ulcers in addition to local care, compression garment, or intermittent compression pump (ICP) in the venous guidelines of the American College of Chest Physicians (ACCP; GRADE 2B).¹³⁶

Diosmin and hesperidin. The effect of a combination of flavonoid drugs, diosmin, and hesperidin, in the form of MPFF, in addition to compression therapy, was evaluated on ulcer healing and symptoms of CVD in an RCT by

Guilhou et al.¹³⁷ Although the overall effect of the drug when combined with compression therapy, was weak, among patients with ulcers measuring ≤ 10 cm, more ulcers healed in the MPFF group than in the placebo group (32% vs 13%; $P = .028$) with a shorter duration of healing ($P = .037$). Sensation of heavy leg was less in patients treated with MPFF ($P = .030$).

A meta-analysis of five RCTs that included 723 patients with venous ulcers was reported by Coleridge-Smith et al.¹³⁰ The study found that at 6 months, the chance of healing an ulcer was 32% better in patients treated with adjunctive MPFF than in those managed by conventional therapy alone (relative risk reduction, 32%; 95% CI, 3%-70%). These results confirm that venous ulcer healing is accelerated by MPFF treatment. For patients with persistent venous ulcers, flavonoids, in the form of MPFF given orally or sulodexide administered intramuscularly and then orally, are suggested in the ACCP guidelines (GRADE 2B).¹³⁶ The SVS/AVF Guideline Committee also suggests that MPFF or pentoxifylline be used for patients with venous ulcers as an adjuvant therapy to compression to accelerate ulcer healing (GRADE 2B).

Compression treatment

Compression therapy is the basic and most frequently used treatment of varicose veins, venous edema, skin changes, and ulcerations. Compression is recommended to decrease ambulatory venous hypertension to patients with CVD in addition to lifestyle modifications that include weight loss, exercise, and elevation of the legs during the day whenever possible.

The different forms of ambulatory compression techniques and devices include elastic compression stockings, paste gauze boots (Unna boot), multilayer elastic wraps, dressings, elastic and nonelastic bandages, and nonelastic garments. Pneumatic compression devices (such as an ICP), applied primarily at night, are also used in patients with refractory edema and venous ulcers.¹³⁸ The rationale

Guideline 8. Medical treatment

<i>Guideline No.</i>	<i>8. Medical treatment</i>	<i>GRADE of recommendation</i>	<i>Level of evidence</i>
		1. Strong	A. High quality
		2. Weak	B. Moderate quality C. Low or very low quality
8.1	We suggest venoactive drugs (diosmin, hesperidin, rutosides, sulodexide, micronized purified flavonoid fraction, or horse chestnut seed extract [aescin]) for patients with pain and swelling due to chronic venous disease, in countries where these drugs are available.	2	B
8.2	We suggest using pentoxifylline or micronized purified flavonoid fraction, if available, in combination with compression, to accelerate healing of venous ulcers.	2	B

of compression treatment is to compensate for the increased ambulatory venous hypertension. Pressures to compress the superficial veins in supine patients range from 20 to 25 mm Hg. When upright, pressures of 35 to 40 mm Hg have been shown to narrow the superficial veins, and pressures >60 mm Hg are needed to occlude them.¹³⁹

Varicose veins (CEAP class C₂). Reported case series of patients treated with elastic stockings frequently included the whole spectrum of patients with CVD (CEAP class C₀-C₆). Treatment with 30 to 40 mm Hg compression stockings in 112 patients (82% with varicose veins, 52% with edema, and 7% with healed or active ulcers) resulted in marked improvement in pain, swelling, skin pigmentation, activity, and well-being at 16 months after initiation of therapy, with compliance of 70%.¹⁴⁰

A large systematic review of compression hosiery for uncomplicated simple varicose veins was recently published by Palfreyman and Michaels.³⁴ They analyzed data of 11 prospective RCTs or systematic reviews, 12 nonrandomized studies, and 2 guidelines. Although compression improved symptoms, the study concluded that evidence is lacking to support compression garments to decrease progression or to prevent recurrence of varicose veins after treatment. However, these results could have been confounded by the high number of noncompliant patients included in these studies.³⁴

The level of compression for patients with class C₂ disease is also disputed. A meta-analysis by Amsler and Blattler¹⁴¹ of 11 RCTs suggested that in healthy patients, in those with C₁ to C₃ disease, and in those after varicose vein surgery, medium compression stockings (>20 mm Hg) may add no benefit over that obtained with a compression of between 10 and 15 mm Hg.

Until further data on appropriate tension of elastic garments are available, for patients with simple varicose veins (class C₂), the SVS/AVF Guideline Committee suggests graded prescription stockings with an ankle pressure of 20 to 30 mm Hg (GRADE 2C). The most common length recommended is knee-high stockings, although thigh-high stockings and pantyhose are also available and may be appropriate for many patients. Skin breakdown and

frank necrosis after incorrectly measured or applied garments have been reported.¹⁴² The Committee recommends that only those with the necessary skills and training prescribe stockings for patients with venous disease.

The efficacy of conservative vs surgical treatment for varicose veins was studied in an RCT by Michaels et al.¹⁴³ The Randomised Clinical Trial, Observational Study and Assessment of Cost-Effectiveness of the Treatment of Varicose Veins (REACTIV) trial randomized 246 patients with simple varicose veins (class C₂) to conservative management or surgery. Conservative treatment included lifestyle advice relating to exercise, leg elevation, management of weight and diet, and the use of compression hosiery. In the surgical arm, patients received the same lifestyle advice but also underwent high ligation, stripping, and phlebectomies. In the first 2 years after treatment, there was a significant QOL benefit for surgery of 0.083 quality-adjusted life-years (QALY; 95% CI, 0.005-0.16 QALY) based on the SF-6D score (derived from scores on six domains of the SF-36) and 0.13 QALY (95% CI, 0.016-0.25 QALY) based on the EQ-5D score (a five-dimension descriptive system of health-related QOL). Considerable benefits were also seen in symptomatic and anatomic measures. The authors concluded that surgery provides more symptomatic relief and improvements in QOL than conservative management with compression hosiery and lifestyle modifications in patients with uncomplicated varicose veins.

The cost-effectiveness of conservative vs surgical therapy or sclerotherapy in patients with varicose veins was also studied in the REACTIV trial.¹⁴⁴ Cost-effectiveness analysis showed that surgery was significantly more cost-effective than both sclerotherapy and conservative management; sclerotherapy was less cost-effective than surgery but was still significantly more cost-effective than conservative treatment.

The need for a period of compression treatment before any intervention for simple varicose veins has been surrounded by controversy. Although third-party payers often require a trial of compression stockings, there is virtually no scientific evidence to support such a policy when saphenous ablation to treat superficial reflux is both more efficacious and

cost-effective, a fact supported by data of the REACTIV trial. In addition, some patients, such as the obese or the elderly, may have difficulties applying an elastic stockings.¹³⁸ One study of predominantly elderly (mean age, 72 years) women with CVD found that 15% could not apply elastic stockings and 26% needed considerable help to do so.¹⁴⁵ On the basis of the available evidence, the Guideline Committee recommends against compression therapy being considered the primary treatment of symptomatic varicose veins (class C₂) in those patients who are candidates for saphenous vein ablation (GRADE 1B).

CVI (CEAP classes C₃-C₆). Compression therapy remains the standard of care for patients with advanced CVD and venous ulcers (class C₃-C₆). Compression therapy improves calf muscle pump function and decreases reflux in vein segments in patients with CVI.^{146,147} In patients with venous ulcers, graded compression is effective as the primary treatment to aid healing of venous ulceration and as adjuvant therapy to interventions to prevent recurrence of venous ulcers.¹⁴⁸

Compliance with compression therapy is important. In a cohort study by Mayberry et al,¹⁴⁸ results of venous ulcer treatment in 113 patients treated over 15 years were reported. Ulcer healing with local care and compression averaged 5.3 months, and was 97% in compliant patients and 55% in noncompliant patients ($P < .0001$). Ulcer recurrence was 16% in compliant patients and 100% in noncompliant patients.

A systematic review of 24 RCTs on compression treatment on venous ulcers by Fletcher et al³⁶ concluded that compression treatment improves the healing of ulcers compared with no compression¹⁴⁹ and that high compression is more effective than low compression.¹⁵⁰ The authors found no evidence that one form of compression treatment is better than another, although a previously published single-center experience suggested that low-stretch inelastic bandages were more effective in reducing venous reflux than elastic bandages.¹⁵¹ The ACCP guidelines suggest the use of an ICP in addition to a compression garment and local care for treatment of recalcitrant ulcers.¹³⁶

A recent meta-analysis by Amsler et al¹⁵² examined data of 692 ulcer patients in eight RCTs and found that ulcer healing was faster, with an average of 3 weeks, with stockings than with bandages ($P = .0002$). Pain, examined in three studies, was also significantly less with stockings than with bandages ($P < .0001$).

Another systematic review by Partsch et al¹⁵³ confirmed (GRADE 1A) that compression bandaging promotes healing of venous ulcers and that strong-compression hosiery (30 to 40 mm Hg) is more effective than medium- or low-compression stockings (GRADE 1B). This study observed GRADE 1A evidence that 30 to 40 mm Hg compression hosiery prevents recurrence of ulceration after healing. A recent evidence summary on ulcers by Coleridge-Smith¹⁵⁴ supported these recommendations.

An RCT by Milic et al¹⁵⁵ compared treatment with tubular compression (35 mm Hg) vs compression bandages (25 mm Hg) in 138 patients with extensive venous

ulceration (ulceration surface, 20-210 cm²; duration, 7 months-28 years). The authors observed a healing rate of 93% in the treatment group vs 51% in the control group ($P < .001$). The recurrence rate at 12 months was 24% in the treatment group and 53% in the control group ($P < .05$). After additional compression treatment with the same treatment protocol, all 16 recurrent ulcers in the treatment group healed. In the control group, the healing rate of recurrent ulcers was 89%. This study suggests that for extensive and long-standing venous ulceration, multilayer tubular compression therapy improves healing and decreases but does not prevent ulcer recurrence.

The Effect of Surgery and Compression on Healing And Recurrence (ESCHAR) study^{156,157} randomized 500 patients with leg ulcers to compression treatment alone or compression combined with superficial venous surgery. Compression consisted of multilayer compression bandaging, followed by class 2 (medium compression, 18-24 mm Hg, British Standard¹⁵⁸) below-knee stockings. Superficial venous surgery included saphenous vein ablation with high ligation and stripping (HL/S) as well as avulsion of varicose veins of the calf. General anesthesia could not be used in 25% of the patients, and in these, high saphenous vein ligation alone was performed.

Compression treatment alone was as effective as compression with surgery to heal venous ulcers (65% vs 65%; hazard ratio, 0.84; 95% CI, 0.77-1.24; $P = .85$), but 12-month ulcer recurrence rates were reduced in the compression with surgery group vs those with compression alone (12% vs 28%; hazard ratio, -2.76; 95% CI, -1.78 to -4.27; $P < .0001$). The difference in ulcer recurrence rates persisted between the two groups at 4 years.¹⁵⁹ A weakness of the trial was that there was no surgical arm without compression. This was unfortunate, because there is some evidence that saphenous vein disconnection improves venous function and heals venous ulcers, even without compression bandaging, if the deep veins are normal.¹⁶⁰

A meta-analysis and Cochrane Collaboration review of 42 RCTs by Palfreyman et al^{42,161} searched for evidence of effectiveness of dressings applied to venous leg ulcers in addition to compression. The authors concluded that there is no evidence that hydrocolloid or other dressings beneath compression are more effective than compression alone.

On the basis of high-quality clinical evidence, the Guideline Committee recommends compression therapy for patients with CVI (class C₃-C₆), including those with leg ulcers. Compression therapy is now considered the primary therapy to aid in healing venous ulcers (GRADE 1B) and the adjuvant therapy to superficial vein ablation to prevent ulcer recurrence (GRADE 1A).

Open venous surgery

Open surgical treatment of varicose veins with ligation and stripping of the GSV or SSV, combined with excision of large varicose veins, has been the standard of care of varicose vein treatment for more than a century. Invagination stripping was first attempted by Keller¹⁶² in 1905, Charles Mayo in 1906¹⁶³ used an external stripper to

Guideline 9. Compression treatment

Guideline No.	9. Compression treatment	GRADE of recommendation	Level of evidence
		1. Strong	A. High quality
		2. Weak	B. Moderate quality C. Low or very low quality
9.1	We suggest compression therapy using moderate pressure (20 to 30 mm Hg) for patients with symptomatic varicose veins.	2	C
9.2	We recommend against compression therapy as the primary treatment of symptomatic varicose veins in patients who are candidates for saphenous vein ablation.	1	B
9.3	We recommend compression as the primary therapeutic modality for healing venous ulcers.	1	B
9.4	We recommend compression as an adjuvant treatment to superficial vein ablation for the prevention of ulcer recurrence.	1	A

remove the saphenous veins, and Babcock in 1907¹⁶⁴ introduced intraluminal stripping from the ankle to the groin. High ligation and ankle-to-groin stripping using a metal or, later, a disposable Codman or Myers stripper has become the technique of choice to remove the saphenous vein. Recognition of frequent saphenous nerve injury during ankle-to-groin stripping and a better understanding of the venous hemodynamics changed the technique to a limited, groin-to-knee stripping.¹⁶⁵

The invagination technique using a silk thread was perfected by Van Der Stricht¹⁶⁶ and using the Myers stripper, without the acorn-shaped head, by Fullarton and Calvert,¹⁶⁷ while perforate invaginate (PIN) stripping was introduced by Oesch¹⁶⁸ and perfected in the United States by Goren and Yellin.¹⁶⁹ Varicose vein excision performed from multiple larger skin incisions^{170,171} was also abandoned, and ambulatory hook phlebectomy^{172,173} and powered phlebectomy¹⁷⁴⁻¹⁷⁶ have been adopted.

During the past decade, endovenous thermal ablation has largely replaced the classic ligation and stripping operation, and open surgery for saphenous incompetence is performed much less frequently in the United States. Indications for ligation and stripping have been restricted to patients with large dilated and tortuous saphenous vein located immediately under the skin or to those with aneurysmal enlargement at the SFJ. Because of previous thrombophlebitis of the GSV or SSV, percutaneous placement of the laser fiber or radiofrequency (RF) catheter may not be possible, and open techniques have to be used for removal of the vein.

It is important to note, however, that the technique of open surgery has also changed substantially in recent years, and today a much less invasive procedure is performed to treat the incompetent saphenous veins than at anytime before. The groin incision is small, the incision at the knee for inversion stripping is either a puncture wound (PIN stripping) or a small stab wound, and the operation is performed under local tumescent anesthesia with increasing frequency.¹⁷⁷ Although endothermal ablations are fa-

vored in the United States, in many countries conventional surgery remains the standard of care of patients with varicose veins.¹⁷⁸

High ligation, division, and stripping of the GSV. The term *high ligation and division* implies ligation and division of the GSV at its confluence with the common femoral vein, including ligation and division of all upper GSV tributaries.⁵¹ Partial or complete preservation of the upper GSV tributaries, when the GSV is ligated, stripped, or ablated, must therefore be clearly stated. The term *stripping* means removal of a long vein segment, usually of the saphenous vein, by means of a device.⁵¹

The SFJ is dissected through a 3- to 4-cm-long oblique incision made in the groin crease just lateral to the femoral artery. The cosmetic appearance of the scar of such an incision is excellent. The SFJ is dissected bluntly and sharply, minimizing injury to the surrounding lymphatic tissue to avoid lymphatic leak or lymphedema. The anterior wall of the common femoral vein is always visualized to ensure accurate ligation of the SFJ. All tributaries are ligated and divided, preferably to the secondary branches,¹⁷⁷ although firm evidence to support the need for this is not available. During dissection of the SFJ, the external pudendal artery is carefully preserved. Flush ligation of the saphenous vein is performed by double-ligating the vein with nonabsorbable suture close to the SFJ. It is important to avoid narrowing the femoral vein but equally important to minimize chances for a cul-de-sac in the saphenous vein stump.

To perform stripping, a flexible Codman stripper is often used for invagination stripping, without the removable acorn. The saphenous vein is tied to the tip of the stripper, and the vein is inverted into its lumen as the stripper is pulled down through a small incision made below the knee. Alternatively, an Oesch PIN stripper can be used.^{168,169} Saphenous stripping below the knee is rarely performed today because of an increased incidence of reported saphenous nerve injury.¹⁶⁵ To decrease bleeding in the saphenous tunnel after stripping, we suggest that the

perisaphenous space be infiltrated with tumescent anesthetic solution.

The operation is usually completed with a miniphlebectomy to remove the bulging varicose veins through a small stab wound. The incisions are then infiltrated with tumescent solutions, the groin incision is closed in layers with nonadsorbable sutures, and the stab wounds are closed with sterile adhesive strips. The extremity is bandaged with an elastic bandage to decrease the risk of bleeding and to decrease swelling and pain. The operation is an outpatient procedure.

High ligation, division, and stripping of the SSV.

Complete stripping of the SSV is rarely performed today because of possible injury to the sural nerve, but ligation of the SSV through a small transverse incision in the popliteal crease can be performed together with a limited invagination stripping of the vein to the mid calf, using the same technique described for GSV stripping. The safest technique to identify the SSV is intraoperative duplex scanning. There is no evidence that flush ligation is better than simple ligation of the vein when performed at a location closer to the skin, usually right in the knee crease. We recommend ligation of the SSV at this level, about 3 to 5 cm distal to the saphenopopliteal junction, since this can be performed through a very small skin incision and it avoids the need for deep dissection in the popliteal fossa, with the potential for associated wound complications or nerve injury.

Cryostripping of the GSV. To decrease hemorrhage within the saphenous tunnel and avoid any incision placed at the level of the knee, the technique of cryostripping has been suggested by some investigators.¹⁷⁹ Cryostripping is an alternative method to invagination stripping.¹⁸⁰ The technique is new in the United States and has not been fully evaluated.

For cryostripping, a cryosurgical system (Erbokryo CA, ERBE Elektromedizin GmbH, Tübingen, Germany), powered by liquid nitrogen, is used. After high ligation is completed, the cryoprobe is inserted into the saphenous vein and passed down to the level of the knee. As soon as the probe tip reaches the desired segment of the GSV, freezing is initiated. After the freezing cycle is maintained for a couple of seconds, the GSV is invaginated with an upward tug and is stripped toward the groin.

Phlebectomy

Ambulatory phlebectomy. Ambulatory phlebectomy (stab or hook phlebectomy or miniphlebectomy) includes removal or avulsion of varicose veins through small stab wounds, made with a No. 11 Beaver blade or a 15° ophthalmologic blade, or through the puncture hole made with a larger, 19-gauge needle. Avulsion of the varicose veins is performed with hooks or forceps.^{172,173} The most widely known hooks are Müller, Oesch, Tretbar, Ramelet, Varady, and Dortu-Martimbeau phlebectomy hooks.^{172,173,181} The veins are marked before surgery on the patient's skin with a marker, with the patient standing. The operation is usually performed under tumescent local anesthesia, using a solution of 445 mL of 0.9% saline, 50

mL of 1% lidocaine with 1:100,000 epinephrine, and 5 mL of 8.4% sodium bicarbonate.¹⁸¹

A rigid cannula with a light source can be used to inject the tumescent solution and also to transilluminate the subcutaneous tissues under the varicose veins.¹⁸² Injection of the tumescent solution can be performed using a large syringe or a Klein infiltration pump.^{181,183} Digital compression is applied immediately, and infiltration of the wound with tumescent solution also provides good hemostasis. The skin incisions are usually approximated with sterile adhesive strips, and compression is applied to the extremity from foot to groin with an elastic compression bandage or compression stocking.

Powered phlebectomy. Transilluminated powered phlebectomy (TIPP; Trivex, InaVein, Lexington, Mass), an alternative technique for the removal of varicose veins, is especially useful for the removal of larger clusters of varicosities.^{184,185} The potential advantages of TIPP include a decrease in the number of incisions and much faster removal of a large amount of varicose vein tissue. Just as for ambulatory phlebectomy, TIPP is often combined with saphenous vein ablation procedures or stripping and ligation to eliminate the source of the reflux underlying a varicose venous cluster formation. Instrumentation includes a central power unit with controls for irrigation pump and resection oscillation speeds, an illuminator hand piece that connects to the control unit using a fiber optic cable and provides high-intensity light for transillumination and delivery of tumescence irrigation, and a resector hand piece that has 4.5-mm and 5.5-mm options.

General, epidural, or spinal anesthesia can be used, depending on patient preference, while local tumescence anesthesia and conscious sedation may be options for limited varicosities in selected patients. In the procedure, TIPP instruments are introduced through tiny incisions. The illuminator produces transilluminated visualization of the veins to be removed, allows delivery of tumescent anesthetic solution, and performs hydrodissection. Through segmental counterincisions under direct visualization, the resector is positioned directly on the varicosity, and with powered endoscopic dissection, varicosities are mobilized free and then suctioned out of the leg. The addition of small 1.5-mm punch incisions allows for blood that collects in the vein tract to be flushed out with further tumescent anesthetic fluid.¹⁸⁴⁻¹⁸⁶

Preservation of the GSV. Preservation of the saphenous vein and treatment of varicose tributaries by phlebectomy has been advocated by Francesci in the CHIVA (*cure conservatrice et hémodynamique de l'insuffisance veineuse en ambulatoire* [ambulatory conservative hemodynamic management of varicose veins]) technique¹⁸⁶⁻¹⁸⁹ and by Pittaluga in the ASVAL (*ablation sélective des varices sous anesthésie locale* [ie ambulatory selective varicose vein ablation under local anesthesia]) technique.¹²⁶

The CHIVA technique. The CHIVA technique is a hemodynamic approach to varicose veins based on the principles of preserving the saphenous vein and venous drainage into the deep system.^{186,190} The goal of CHIVA

is to decrease the hydrostatic pressure in the saphenous veins and tributaries by the ligations placed in specific areas in the superficial venous system and to maintain the drainage function of the superficial veins, usually via a reversed flow.¹⁸⁶ It represents a systematic approach to varicose veins rather than a single operative procedure.

Several anatomic patterns of reflux have been identified, each requiring a somewhat different operative strategy based on the underlying anatomy, studied in utmost detail with duplex scanning.¹⁸⁸ A frequently used CHIVA technique presented in an RCT included proximal ligation of the incompetent saphenous vein; ligation, division, and avulsion of the incompetent varicose tributaries; and maintaining patency of the saphenous trunk, the competent saphenous tributaries, and saphenous venous drainage to the deep system through the so-called reentry perforators.¹⁹¹ A recently published RCT presented further details of the technique in six different types of varicosity.¹⁹²

The ASVAL technique. Described by Pittaluga et al,¹²⁶ the ASVAL operation includes preservation of the incompetent saphenous vein and stab phlebectomy of all varicose tributaries. Most patients operated on with this technique in one study had a less advanced stage of varicosity (CEAP class C₂) and presented with no symptoms in 33% and no trophic skin changes in 91%.¹²⁶

Perioperative thrombosis prophylaxis. Selective prophylaxis after risk assessment is warranted in patients who undergo venous surgery. The risk of DVT is increased in patients with thrombophilia, in those with a history of DVT or thrombophlebitis, and in obese patients. Similarly to the recently published ACCP guidelines,¹⁵⁹ we recommend, for patients who do not have additional thromboembolic risk factors, that surgeons not routinely use specific thromboprophylaxis other than early and frequent ambulation (GRADE 2B). For those with additional thromboembolic risk factors, we recommend thromboprophylaxis with low-molecular-weight heparin, low-dose unfractionated heparin, or fondaparinux (GRADE 1C).

Results of open venous surgery. Results of open surgery have continued to improve during the past decades, and HL/S of the GSV performed as an outpatient procedure is a safe and effective operation. Surgical treatment is superior to conservative management of varicose veins with use of elastic garments. In the REACTIV trial,¹⁴⁴ as discussed previously, results of surgery with compression treatment were compared with results of compression treatment alone in 246 patients with uncomplicated varicose veins.¹⁴³ Surgical treatment included flush ligation of sites of reflux, stripping of the GSV, and multiple phlebectomies. At 2 years, surgery provided more symptomatic relief, better cosmetic results, and much-improved QOL over conservative management.

Marked improvement in QOL after open surgery was also demonstrated in an RCT by Rasmussen et al.¹⁷⁷ In a prospective cohort study, Mackenzie et al¹⁹³ monitored 102 consecutive patients who underwent varicose vein surgery. At 2 years after surgery, health-related QOL markedly improved to baseline when assessed with the Aberdeen

Varicose Vein Symptom Severity Score and the SF-36. Improvement in QOL from varicose vein surgery has been shown to be statistically significant and clinically meaningful, matching the benefits observed after elective laparoscopic cholecystectomy.¹⁹⁴

Recovery after conventional high ligation and inversion stripping with associated phlebectomies has been variable in different reports. In a series of 112 procedures performed in an office setting under locoregional anesthesia, using high ligation, PIN stripping, and hook phlebectomy, Goren and Yellin¹⁶⁹ reported that all their patients resumed normal daily and sporting activities immediately after surgery and none had major complications. There was frequent bruising, but no tract hematomas, no nerve damage, and no DVTs were noted in this series. Follow-up of this series, however, was poor and the quality of evidence of treatment efficacy was low.

In an RCT that compared high ligation, stripping, and phlebectomy with RFA and phlebectomy, the open surgical group at 3 weeks had a 2.8% wound infection rate, 19.4% of the patients had ecchymosis, 33.3% had hematoma, and 5.6% had paresthesias.¹⁹⁵ Most importantly, time to return to normal activities averaged 3.89 days (95% CI, 2.67-5.12 days; $P = .02$), only 46.9% of patients returned to routine daily activities within 1 day, and the number of days to return to work averaged 12.4 days (95% CI, 8.66-16.23 days).

HL/S vs high ligation alone. HL/S of the GSV reduced the risk of reoperation by two-thirds at 5 years after surgery in a prospective randomized study reported by Dwerryhouse et al.¹⁹⁶ The authors randomized 133 legs of 100 patients to high ligation or HL/S. The need for reoperation was 6% in patients who underwent HL/S vs 20% in those patients who underwent high ligation alone ($P > .02$). The reason for this is that patients with only high ligation have recurrent reflux in the residual GSV, which causes new symptoms and increases the risk of reoperation.

The effect of saphenous stump closure on outcome. In an RCT, Frings et al¹⁹⁷ found more neovascularization in patients who had the endothelium of the saphenous stump exposed vs those who had the saphenous stump oversewn with a running nonabsorbable polypropylene suture. (Neovascularization has been defined as the presence of multiple new small tortuous veins in anatomic proximity to a previous venous intervention.⁵¹) No conclusion could be reached, however, on the type of suture used to ligate the stump. Neoreflux was the same after ligation with absorbable suture vs nonabsorbable suture.

An RCT by Winterborn et al¹⁹⁸ observed no difference in varicose vein recurrence if a standard saphenofemoral ligation (transfixation and ligation using nonabsorbable suture, with exposed endothelium of the stump) or a flush saphenofemoral ligation (the stump was oversewn with a running polypropylene suture, with no endothelium exposed) was used. At 2 years, the recurrence rate was 33% in the standard group and 32% in the flush group ($P = .90$). Neovascularization was present in 22% in standard group and in 19% in the flush group ($P = .57$).

Another RCT on 389 limbs by van Rij et al¹⁹⁹ observed that placement of a polytetrafluoroethylene (PTFE) patch over the SFJ halved recurrence at 3 years compared with controls and that a synthetic patch was an effective mechanical suppressant of neovasculogenesis at the groin. These findings were not confirmed, however, in a smaller RCT by Winterborn and Earnshaw.²⁰⁰ This study randomized 40 legs to insertion or no insertion of a PTFE patch over the ligated SFJ. The overall complication rate was 35% (11 legs), with no statistically significant difference between the groups. By 2 years postoperatively, duplex imaging showed neovascularization had developed at the SFJ in 4 of 16 legs without a patch and in 5 of 16 legs with a patch ($P = 1.0$). We recommend double ligation of the SFJ with nonabsorbable suture (GRADE 1C), but we suggest against using a PTFE patch to cover the saphenous stump (GRADE 2C).

Complications. Wound complications usually occur in 3% to 10% of patients,^{178,201} with reported wound infection rates as low as 1.5% and as high as 16%.²⁰²⁻²⁰⁴ An RCT by Biswas et al²⁰⁵ evaluated the efficacy of the duration of compression therapy in 300 postsurgical patients. The study found no benefit in wearing compression stockings for >1 week after uncomplicated HL/S of the GSV with respect to postoperative pain, number of complications, time to return to work, or patient satisfaction for up to 12 weeks after surgery.²⁰⁵

In a recent RCT that included 443 patients who underwent groin surgery for varicose veins, the risk of wound infections and wound-related complications was reduced with use of a single dose of perioperative antibiotic prophylaxis.²⁰⁶ Wound outcomes were worse with higher body mass index (OR, 0.92; 95% CI, 0.87-0.97; $P = .005$) and with current smoking (OR, 0.5; 95% CI, 0.3-0.9; $P = .033$).²⁰⁶

Nerve injury. Using conventional stripping techniques, the incidence of saphenous nerve injury in one study was 7% in patients who had stripping to the knee and 39% in those who had stripping to the ankle.¹⁶⁵ Sural nerve injury occurred at a rate of 2% to 4%. Common peroneal nerve injury occurred in 4.7% in one series and in 6.7% in another series in those patients who underwent SSV ligation or stripping.²⁰⁷

Injury to the femoral artery and vein. Injury to the femoral vein or artery during high ligation of the saphenous vein is, fortunately, very rare. Consequences can be disastrous, because most are not recognized immediately,²⁰⁸ and a delay in treatment may result in massive DVT or even loss of the limb from the severe arterial injury.

Thromboembolic complications. DVT and pulmonary embolism (PE) are rare but occasionally serious complications of superficial vein surgery. In a prospective study, Van Rij²⁰⁹ performed duplex scanning in 377 patients before surgery and then at 2 to 4 weeks and at 6 to 12 months after surgery. Acute DVT was detected in 20 patients (5.3%). Eight were symptomatic and no PE was observed. Although this series suggests an incidence of DVT that is higher than previously believed, this complication had minimal short-term or long-term clinical significance. Of the

20 DVTs, 18 were confined to calf veins, and half of the DVTs had resolved without deep venous reflux at 1 year. Others reported an incidence of 0.5% for DVT and 0.16% for PE.²⁰¹

Conventional stripping vs cryostripping. An RCT by Menyhei et al¹⁷⁹ randomized 160 patients to high ligation, division, and cryostripping vs conventional stripping. No differences in QOL measures were noted by the SF-36 questionnaire at 6 months between the two groups. Bruising was more frequent after conventional stripping ($P = .01$), but there was no difference in pain score or complications. Two patients from the conventional stripping group and six from the cryostripping group were excluded from analysis because of incomplete stripping. Experience with this technique in the United States is limited, and at this time no recommendation is made.

Results of superficial vein surgery on ulcer healing and recurrence. High quality evidence indicates that superficial vein surgery reduces ulcer recurrence. The ESCHAR study,^{156,157} as discussed earlier, randomized 500 patients with leg ulcers, who had isolated superficial venous reflux or mixed superficial and deep reflux, to compression treatment alone or to compression combined with superficial venous surgery. Compression consisted of multilayer compression bandaging, followed by class 2 below-knee stockings. Surgery included high ligation, division, and saphenous stripping. Rates of healing at 24 weeks were similar in both groups (65% vs 65%; hazard ratio, 0.84; 95% CI, 0.77-1.24; $P = .85$), but 12-month ulcer recurrence rates were reduced in the compression with surgery group (12% vs 28%; hazard ratio, -2.76; 95% CI, -1.78 to -4.27; $P < .0001$). The difference in ulcer recurrence rates between the two groups at 4 years was significant.¹⁵⁷

Powered phlebectomy vs stab phlebectomy. A limited number of studies, both retrospective and prospective, have been performed. Overall, reported complications after TIPP have varied considerably and include ecchymosis and hematoma in 4.9% to 95%, paresthesias and nerve injury in 9.5% to 39%, skin perforation in 1.2% to 5%, superficial phlebitis in 2.4% to 13%, swelling in 5% to 17.5%, hyperpigmentation in 1.2% to 3.3%, residual or recurrent varicose veins in 9.1% to 21.2%, and DVT in <1%.^{174,210} In a comparison between TIPP and stab phlebectomy, TIPP revealed a difference in the number of incisions¹⁷⁴ and in the speed of the procedure.^{178,179} However, there was no difference in bruising, cellulitis, and numbness at 1 to 2 weeks; nerve injury, residual veins, cosmesis score, and overall satisfaction at 6 weeks; and cosmesis or recurrence at 6 and 12 months. A learning curve to determine just how aggressive the surgeon can be during the procedure to eliminate all veins while minimizing bruising and other local complications has also been noted.^{211,212} These reports, however, used an early-generation system, higher oscillation speeds (800-1200 rpm), and minimal tumescence.

With a newer-generation system and technical modifications incorporating a lower oscillation frequency (300-

500 rpm), a dermal punch drainage technique, secondary tumescence with extensive flushing of residual hematoma and residual venous tissue fragments, and an additional tertiary subdermal tumescence phase, the results of powered phlebectomy have improved.²¹³ The largest series²¹⁴ using modified techniques included 339 patients with a mean operative time of 19.7 minutes, and >60% of cases involving 10 to 20 incisions. Discoloration of the skin was noted in eight patients (2.3%), excessive or hypertrophic scarring in two (0.6%), and cellulitis in one (0.3%). There were no significant hematomas and no recurrent varicose veins at 12 weeks in this series, and overall, 99.7% reported good outcomes and satisfaction.

Although no published data clearly show any statistically significant advantage of TIPP over conventional phlebectomy except for fewer incisions, most published literature represents earlier-generation systems and techniques. With the newer-generation system and modified technique and learning curve adjustments, TIPP has become less traumatic, which may decrease potential complications and improve outcomes over those previously reported. Until new trials are performed, any additional potential benefits of TIPP have yet to be substantiated.

Results with preservation of the saphenous vein. *Results with CHIVA.* Two RCTs^{188,191} compared standard treatment (compression or high ligation, stripping, and phlebectomy) with CHIVA approaches with specific anatomic patterns of reflux (types I and III shunts). For the specific venous anatomy evaluated in these trials, such techniques were better than compression in preventing ulcer recurrence¹⁸⁸ and were at least equivalent to stripping of varicose veins.¹⁹¹

In a single-center RCT, Zamboni et al¹⁸⁸ used CHIVA or compression to treat 47 legs with venous ulcers. At a mean follow-up of 3 years, healing was 100% (median healing time, 31 days) in the surgical group and 96% (median healing time, 63 days) in the compression group ($P < .02$). The recurrence rate was 9% in the surgical group and 38% in the compression group ($P < .05$). The study excluded patients with post-thrombotic syndrome, deep vein reflux or obstruction, or excessive ulcers (>12 cm).

In a recent open-label, single-center RCT, Pares et al¹⁹² randomized 501 patients with primary varicose veins into three arms: CHIVA, stripping with clinic marking, and stripping with duplex marking. The primary end point was recurrence within 5 years, assessed clinically by independent observers. Clinical outcomes in the CHIVA group were better (44.3% cure, 24.6% improvement, 31.1% failure) than in the stripping with clinic marking (21.0% cure, 26.3% improvement, 52.7% failure) and stripping with duplex marking (29.3% cure, 22.8% improvement, 47.9% failure) groups. The OR between the stripping with clinic marking and CHIVA groups, of recurrence at 5 years of follow-up, was 2.64 (95% CI, 1.76-3.97; $P < .001$). The OR of recurrence at 5 years between the stripping with duplex marking and CHIVA group was 2.01 (95% CI, 1.34-3.00; $P < .001$).

Although the first two RCTs focused on a small group of patients with varicose veins, the trial of Pares et al¹⁹² deserves credit for including the full spectrum of patients with primary varicose veins. CHIVA is a complex approach, and a high level of training and experience is needed to attain the results presented in this RCT. However, the results achieved by a few outstanding interventionists does not support offering this procedure to all practitioners. Although CHIVA has called attention to the importance of directing surgical procedures toward the patient's venous anatomy and function, it still requires considerable education of venous interventionists willing to learn this approach.

Results with ASVAL. Good clinical results have been reported with the ASVAL procedure in a select group of patients. After 4 years of follow-up, no reflux or minimal reflux (<500 ms) was found in 66.3% of 303 limbs, and symptoms improved in 78% and varicose vein recurred in only 11.5%.¹²⁶

Current selection criteria for the ASVAL procedure include patients with mild CVD, with either a competent terminal valve or segmental saphenous reflux, and no or minimal symptoms. Most had a GSV diameter <8 mm or SSV diameter <6 mm. Although promising in this group of patients with largely cosmetic concerns, the technique is not generalizable and has not been evaluated in any comparative studies against well-validated surgical techniques (GRADE 2C).

Recurrent varicose veins. Recurrent varicose veins after surgical treatment are a serious problem, and many patients require additional interventions. Surgery for recurrence represents a considerable proportion of the workload of surgeons operating on varicose veins. The operations are technically more demanding and complicated than first-time operations.

Recurrent varicose veins after surgery (REVAS) have been reported at rates ranging from 6.6% to 37% at 2 years^{177,215,216} and up to 51% at 5 years.²¹⁷⁻²²² Most studies reported 2-year clinical recurrence rates of 20% to 37% after conventional or cryostripping, when residual or recurrent varicose veins noted by both the patient and the surgeon were counted.^{216,220} In a 34-year follow-up study of 125 limbs, Fischer et al²²¹ noted ultrasonographic evidence of saphenofemoral reflux in 75 limbs (60%). Allegra et al²¹⁹ noted a 5-year recurrence rate of 25% in a large study that included 1326 patients. Despite technically correct surgery, confirmed with postoperative duplex scanning, recurrence at the SFJ occurred in 13%, at the saphenopopliteal junction in 30%, and at both in 36%. Factors predicting recurrence were SSV reflux, perforating vein incompetence, and post-thrombotic deep vein incompetence.

A consensus document on REVAS found that the main reasons for recurrence after surgery were technical and tactical errors, neovascularization at the groin, and progression of the underlying disease.²¹⁷ In a multicenter registry that included 199 limbs of 170 patients with REVAS, the most frequent sources of recurrent reflux were the SFJ

(47.2%), followed by leg perforators (54.7%), neovascularization (20%), and technical failure (19%); both neovascularization and technical failure occurred in 17%, and in 35%, the cause was uncertain or unknown.²¹⁵ In a study of 279 limbs with recurrent varicose veins at the groin, Geier et al²²³ found a long residual saphenofemoral stump in about two-thirds of cases, recurrences became apparent after a mean time interval of 6.3 years, and symptoms occurred after a mean of 8.5 years.

Evaluation. Treatment of symptomatic recurrent varicose veins should be performed after careful evaluation of the patient with duplex scanning to assess the etiology, source, type, and extent of recurrent varicose veins. Sites of reflux at the SFJ or saphenopopliteal junction and at the sites of clinically important perforating veins should be searched. Duplex scanning is excellent in identifying residual saphenous stumps, but it has a sensitivity of 62% and a positive predictive value of only 26% to identify correctly the presence of neovascularization.²²⁴ Histologic examination is still the gold standard when trying to differentiate between different types of groin recurrences. If perineal or medial thigh varicosity suggests pelvic reflux, evaluation with transvaginal ultrasonography may be used, although the gonadal and pelvic veins are best evaluated with MR or contrast venography.^{225,226}

Techniques and results of treatment. Ambulatory phlebectomy, sclerotherapy, or endovenous thermal ablation of accessory saphenous or perforating veins can be performed, depending on the source, location, and extent of recurrence. Conventional open surgery usually involves repeat disconnection of the SFJ combined with ambulatory phlebectomy. The SEPS procedure to treat incompetent perforating veins in patients with advanced disease (class C₅-C₆) can be useful. Endovenous thermal ablation can also be performed to treat persistent great, small, or accessory saphenous veins or perforators, and foam sclerotherapy has been used successfully, alone or with phlebectomy, to treat recurrent varicose veins and perforating veins.²²⁷

Phlebectomy alone, without repeat ligation of the saphenous stump, was studied by Pittaluga et al²²⁸ for treatment of recurrent varicose veins in 473 limbs. After 3 years of follow-up, those with phlebectomy alone and those with phlebectomy and stump ligation had similar rates of freedom from inguinal reflux (90.8% vs 92.9%) and from varicose repeat-recurrence (90.8% vs 91.9%), suggesting that the increased complications of groin reoperations can be avoided in some patients.

In a prospective nonrandomized trial, recurrent varicosity was treated by van Groenendaal et al²²⁹ in 149 limbs with open surgery and in 67 with EVLA. Wound infections (8% vs 0%; $P < .05$) and paresthesias (27% vs 13%; $P < .05$) were more frequent in the surgery group, whereas the EVLA group reported more perioperative pain or tightness (17% vs 31%; $P < .05$). Hospital stay in the surgery group was longer ($P < .05$) as was the delay before resuming work (7 vs 2 days; $P < .0001$). At 25 weeks of follow-up, repeat recurrences were reported in 29% after surgery and in 19% after EVLA ($P = .511$). Similar results were reported by the

same authors in patients who underwent open surgery or EVLA for recurrent varicose veins of the SSV.²³⁰ These nonrandomized studies provide only low-quality evidence that EVLA, when possible to perform, results in lower complication rates and better socioeconomic outcome in patients with recurrent varicose veins than open surgery.

Creton and Uhl²²⁷ treated 129 limbs with recurrent varicose veins using foam sclerotherapy with 1% polidocanol combined with surgical treatment. All patients had phlebectomies, and 20 had repeat ligation of the saphenous stumps. Foam sclerotherapy combined with surgery resulted in 93% closure of the saphenous stumps and no recurrent varicose veins. Two patients had asymptomatic DVT. Another study, by O'Hare et al,²³¹ found no difference in occlusion rate of primary and recurrent varicose veins (75% vs 72%) at 6 months when treated with ultrasonographically guided foam sclerotherapy.

Endovenous thermal ablations

Endovenous thermal ablation of the saphenous veins is a relatively new, minimally invasive percutaneous procedure with several advantages over standard open surgery.²³² It requires local tumescent anesthesia and is an outpatient procedure that can be performed in an office setting. The procedure is done under ultrasonographic guidance using percutaneous catheter placement; patients complain less of pain and discomfort and return to work earlier than after open surgical procedures. Endovenous thermal ablation includes EVLA and RFA (Table VI). A third technique that recently emerged includes the use of superheated steam, which destroys the endothelial layer and causes shrinkage of the collagen.²³³ Early clinical application, as reported by Milleret et al,²³³ is promising, but available data are not sufficient to include this technique in our report in more detail. EVLA and RFA are similar techniques in many ways, so a discussion of concepts and data applying to both of these procedures is appropriate.

Occlusion (ablation) of the treated vein is achieved by heat delivered into the vein through the percutaneously placed laser fiber or an RF catheter. Endovenous thermal ablation causes a direct thermal injury to the vein wall, resulting in destruction of the endothelium, collagen denaturation of the media, and fibrotic and thrombotic occlusions of the vein. The endothermal ablations by laser also provide direct heat injury to the blood.²³⁴ Blood coagulates at 70°C to 80°C, steam bubbles form at 100°C, and carbonization of coagulum is observed at 200°C to 300°C. Currently available laser fibers include hemoglobin-specific laser wavelengths (810, 940, and 980 nm) and water-specific laser wavelengths (1319, 1320, and 1470 nm).

Laser treatment was first recommended by Puglisi²³⁵ in 1989, but it was 10 years later that Boné²³⁶ reported the first successful clinical application of a diode laser for the treatment of varicose veins. Boné et al²³⁷ reported EVLA first in the English literature in 2001, and the technique was soon adopted and perfected in the United States and worldwide.^{7,238-250}

Guideline 10. Open venous surgery

<i>Guideline No.</i>	<i>10. Open venous surgery</i>	<i>GRADE of recommendation</i>	<i>Level of evidence</i>
		1. Strong	A. High quality
		2. Weak	B. Moderate quality C. Low or very low quality
10.1	For treatment of the incompetent great saphenous vein, we suggest high ligation and inversion stripping of the saphenous vein to the level of the knee.	2	B
10.2	To reduce hematoma formation, pain, and swelling, we recommend postoperative compression. The recommended period of compression in C ₂ patients is 1 week.	1	B
10.3	For treatment of small saphenous vein incompetence, we recommend high ligation of the vein at the knee crease, about 3 to 5 cm distal to the saphenopopliteal junction, with selective invagination stripping of the incompetent portion of the vein.	1	B
10.4	To decrease recurrence of venous ulcers, we recommend ablation of the incompetent superficial veins in addition to compression therapy.	1	A
10.5	We suggest preservation of the saphenous vein using the ambulatory conservative hemodynamic treatment of varicose veins (CHIVA) technique only selectively in patients with varicose veins, when performed by trained venous interventionists.	2	B
10.6	We suggest preservation of the saphenous vein using the ambulatory selective varicose vein ablation under local anesthesia (ASVAL) procedure only selectively in patients with varicose veins.	2	C
10.7	We recommend ambulatory phlebectomy for treatment of varicose veins, performed with saphenous vein ablation, either during the same procedure or at a later stage. If general anesthesia is required for phlebectomy, we suggest concomitant saphenous ablation.	1	B
10.8	We suggest transilluminated powered phlebectomy using lower oscillation speeds and extended tumescence as an alternative to traditional phlebectomy for extensive varicose veins.	2	C
10.9	For treatment of recurrent varicose veins, we suggest ligation of the saphenous stump, ambulatory phlebectomy, sclerotherapy, or endovenous thermal ablation, depending on the etiology, source, location, and extent of varicosity.	2	C

Table VI. Main manufacturers of endovenous ablation devices and laser wavelengths

<i>Device</i>	<i>Manufacturer</i>	<i>Wavelength, nm</i>
Laser device name		
VenaCure EVLT System	AngioDynamics, Inc, Queensbury, NY	810
Medilas D FlexiPulse	Dornier MedTech, Kennesaw, Ga	940
Pro-V	Sciton Inc, Palo Alto, Calif	1319
Vari-lase bright tip, Vari-lase platinum bright tip	Vascular Solutions, Inc, Minneapolis, Minn	810, 980
Cooltouch CTEV	CoolTouch Inc, Roseville, Calif	1320
ELVeS PL Laser System	Biolitec Inc, East Longmeadow, Mass	1470
Radiofrequency device name		
ClosureFast	VNUS Med Tech, San Jose, Calif	
ClosureRFS Stylet	VNUS Med Tech, San Jose, Calif	
Celon RFITT	Olympus Medical Systems, Hamburg, Germany	

The use of RF for saphenous ablation was approved by the U.S. Food and Drug Administration (FDA) in 1999, and the first reports were published in 2000.²⁵¹⁻²⁵³ Experience with RF rapidly accumulated,^{8,195,246,254-259} although the first-generation device was somewhat cumbersome to use. The current ClosureFast RF catheter (VNUS Medical Technologies, San Jose, Calif), introduced in 2007, is more user-friendly, and treatment with it is faster than with the first-generation device.²⁶⁰ This rendition does not need an irrigation system, and the entire pullback

procedure takes 3 to 4 minutes. A second RFA system for bipolar RF-induced thermotherapy, Celon RFITT, is now available in Europe (Olympus Medical Systems, Hamburg, Germany).²⁶¹ This system generates heat at 60°C to 85°C and operates with a continuous pullback technique at a pullback speed of 1 cm/s. Clinical studies to investigate the efficacy of this device are under way.

Patient selection. To select the right patient for endovenous thermal ablation, thorough preprocedural duplex ultrasonography must be performed. The identifica-

tion of all refluxing venous segments and their ablation during the procedure is the key to minimizing recurrence of varicose veins. Inappropriate vein size (<2 mm and >15 mm for RFA), a history of superficial thrombophlebitis resulting in a partially obstructed saphenous vein, and the uncommon occurrence of a tortuous GSV on duplex examination are potential contraindications. Patients with rope varicose veins located immediately under the skin or those with aneurysmal dilations of the SFJ are probably better served with conventional high ligation, division, and stripping. Those with extensive deep venous occlusion should undergo superficial ablation selectively, because superficial veins in these patients may be important for venous outflow from the leg.

There are no absolute contraindications to EVLA, including vein diameter, although Lawrence et al²⁶² have recently suggested an association of central GSV diameter >8 mm with increased risk of extension of thrombus into the femoral vein. Other relative contraindications to endovenous saphenous vein ablation (EVLA or RFA) include uncorrectable coagulopathy, liver dysfunction limiting local anesthetic use, immobility, pregnancy, and breastfeeding.

Technique. The techniques of vein ablations using EVLA or RFA are similar. For GSV ablation, the patient is placed in the reverse Trendelenburg position first, and the GSV is accessed percutaneously under ultrasonographic guidance using a micropuncture needle inserted into the vein just distal to the knee. Treatment is usually limited to the above-the-knee segment of the vein to avoid injury to the saphenous nerve, which is close to the saphenous vein in the calf (Fig 1). A microguidewire is inserted in the vein, followed by placement of a 4F microsheat. With the help of a floppy guidewire, the sheath is exchanged for a 5F sheath, allowing placement of the laser fiber or for an 11-cm-long 7F sheath for placement of the RF catheter.

The laser fiber or RF probe is introduced through the sheath into the GSV and advanced proximally to the SFJ. The tip of the catheter is then positioned 1 cm distal to the confluence with the superficial epigastric vein or 2 cm distal to the SFJ. The patient is then placed in the Trendelenburg position and the vein emptied by elevation and compression by instillation of perivenous tumescent anesthesia with a diluted anesthetic solution (100-300 mL of the 500-mL solution of 445 mL of 0.9N saline, 50 mL of 1% lidocaine with 1:100,000 epinephrine, and 5 mL of 8.4% sodium bicarbonate)²³² into the saphenous subcompartment. The vein can be further compressed by applying negative pressure in the side port with a 20-mL syringe. Tumescent anesthesia enhances contact of the vein wall with the catheter or laser fiber for therapeutic effectiveness and provides analgesia and a heat sink around the treated vein, thereby decreasing heat-related injury to surrounding tissues, which is reflected in a lower incidence of skin burns and paresthesias.

The vein is then ablated in a retrograde fashion to just above the puncture site. The laser fiber is withdrawn at a rate of 1 to 2 mm/s for the first 10 cm and 2 to 3 mm/s for

the remaining distance. For optimal treatment, 50 to 80 J/cm energy is delivered when using the 810-nm diode laser. With the RF catheter system, sequential heating of the vein is performed at 7-cm intervals, heating the vein to 120°C in each 20-second cycle. The first segment is treated twice. At the end of the procedure, the saphenous vein is reimaged to confirm successful obliteration and absence of thrombus protrusion into the femoral vein or, if the SSV was treated, into the popliteal vein. If a patent segment is identified, re-treatment is advisable.

Postprocedural care. Graduated compression stockings with an ankle pressure of 30 to 40 mm Hg or an elastic or nonelastic wrap is placed on the leg at the end of the procedure. Early ambulation is encouraged, and the patient leaves for home a few hours after the procedure. Recent evidence supports elastic compression for at least 1 week after superficial venous interventions.²⁰⁵ During this time, the patient is asked to have compression of the leg day and night. Although the risk of DVT, heat-induced thrombus extension, or PE is rare^{263,264} and therefore the yield is low, we suggest postprocedural duplex scanning within 24 to 72 hours to exclude any thrombotic complication. Evidence to support this recommendation is of low quality (GRADE 2C).

Thrombosis prophylaxis. Data to support the routine administration of thromboprophylaxis with heparin are not available. Selected patients with a history of thrombophlebitis, DVT, known thrombophilia, or obesity are candidates for thrombosis prophylaxis.¹⁵⁹ In one case series, age >50 years was a predictor of heat-induced thrombus extension into the femoral vein.²⁴⁶ Lawrence et al²⁶² reported 500 patients who underwent RFA, and 13 (2.6%) experienced thrombus bulging into the femoral vein or adherent to its wall, which was treated with low-molecular-weight heparin. All of these patients had thrombus retraction to the level of the SFJ in an average of 16 days. A significantly higher rate of proximal thrombus extension was noted in those patients with a history of DVT and in those with a GSV diameter of >8 mm ($P < .02$).

For high-risk patients, several interventionists use a single, preventive dose of low-molecular-weight heparin before or at the beginning of the procedure, although data on the effectiveness of such prophylaxis are not available.²⁴⁶ Performing the operation as an outpatient procedure under local or tumescent anesthesia permits early ambulation that decreases the risk of thromboembolic complications. In addition, the use of elastic compression and frequent leg elevation are also aimed at prevention of DVT or PE.

Results of EVLA. Early results from Navarro et al²³⁷ in 40 patients confirmed 100% saphenous occlusion at 4.2 months and suggested rapid and widespread use of this therapy. Min et al²⁶⁶ reported 3-year results in 499 legs treated with laser, demonstrating a saphenous occlusion rate of 93%. In a large single-center cohort study, Myers and Jolley²⁶⁴ treated 509 limbs with an 810-nm laser during a 5-year period. The rate of primary occlusion at 4 years was 76%, and the secondary occlusion rate was 97%. A systematic review of EVLA for varicose veins by Mundy et

al⁷ found an early saphenous occlusion rate of 88% to 100%, and a review of 13 studies showed evidence of short-term benefits.

EVLA of the SSV has been described by several groups.²⁶⁶⁻²⁶⁸ Proebstle et al²⁶⁰ observed a 100% occlusion rate at 6 months by using a 940-nm diode laser to treat the SSV in 41 patients. In a prospective cohort study, Huisman et al²⁶⁷ treated the SSV in 169 limbs with an 810-nm diode laser. The treated length averaged 23 cm (range, 6-53 cm). Occlusion of the SSV after 3 months was achieved in 98%.

Knipp et al²⁶⁸ reported a 1-year saphenous occlusion rate of 95.9% in 460 limbs treated with 810-nm EVLA and observed sustained improvement using the VCSS. These authors also found that outcomes were not affected by the presence or absence of deep vein insufficiency.

Complications. In an international endovascular working group registry that included 3696 procedures, bruising after EVLA was observed in 75%, paresthesia in 3%, thrombophlebitis in 1.87%, skin burns in 0.46%, and DVT or endovenous heat-induced thrombosis in 0.27%.²⁶³ Only one patient had a PE. In 509 patients treated with laser by Myers and Jolley,²⁶⁴ thromboembolic complications occurred in 3%. Knipp et al²⁶⁸ observed a DVT rate of 2.2% in patients who underwent EVLA with phlebectomy or perforator ligation and a thrombus extension rate into the femoral veins of 5.9%. When EVLA alone was performed, there was 0% true DVT but a high thrombus extension rate (7.8%) into the femoral vein. The risk-adjusted thrombosis prevention protocol in this study had no effect on thrombus extension rate into the femoral vein. Puggioni et al²⁴⁶ observed a 2.3% rate of thrombus extension into the femoral vein after EVLT.

Laser treatment of the SSV may result in sural nerve paresthesia, with an incidence of 1.3% in the series of Huisman et al.²⁶⁷ Superficial thrombophlebitis developed in 6 of 169 patients (3.5%) in this study, but serious complications did not occur.

Laser wavelength, radial fiber, and efficiency. Evidence to support the efficiency of higher-wavelength vs lower-wavelength laser fibers has been controversial. A prospective, randomized, single-center, single-surgeon trial evaluated lasers with 810- or 980-nm wavelengths.²⁴³ Thirty legs were treated for each group by a surgeon blinded for the type of laser. Patients in the 980-nm group showed less bruising than those in the 810-nm group ($P < .005$). Saphenous occlusion rates at 1 year, however, were identical, and no major complications occurred in either group. Studies by Proebstle et al²⁴⁰ and Pannier et al,²⁶⁹ however, suggest that laser light with longer wavelengths (1320-nm Nd:YAG laser, 1470-nm diode laser) may reduce adverse effects without compromising abolition of reflux.

Another recent development is the introduction of the ELVeS Radial Fiber, a fiber with a radial emitting laser tip (Biolitec AG, Jena, Germany), which may decrease the amount of energy required to occlude the vein, thus decreasing pain and adverse effects of thermal ablations. A

RCT by Doganci and Demirkilic²⁷⁰ compared early occlusion rates of two different laser fibers. The immediate occlusion rate was 100% for both the 980-nm laser and bare-tip fiber and the 1470-nm laser with the radial fiber. Other clinical trials with such fibers are under way.

EVLA vs high ligation, division, and stripping. Seven RCTs^{250,265,271-275} compared results of laser ablation with open high ligation, division, and saphenous stripping. An RCT by Rasmussen et al²⁶⁵ found no difference in short-term safety and efficacy or early QOL between EVLA using a wavelength of 980 nm and HL/S, but EVLA was more expensive than open surgery. The recurrence rate of varicose veins at 2 years was 33% after high ligation and 26% after EVLA ($P = NS$).¹⁷⁷ The study concluded that treatments were equally safe and efficient in eliminating saphenous reflux, alleviating symptoms and signs of varicose veins, and improving QOL.

Darwood et al²⁷¹ performed an RCT comparing EVLA with surgery for treatment of primary varicosity and saphenous incompetence. EVLA and surgery were comparable in ablation of reflux and in disease-specific QOL, but return to normal activity averaged a median of 2 days (range, 0-7 days) after EVLA vs 7 days (range, 2-26 days) after surgical treatment ($P = .001$). Return to work was 4 days (range, 2-7 days) after EVLA vs 17 days (range, 7.25-33.25 days) after surgery ($P = .005$), suggesting important socioeconomic advantages for EVLA. These RCTs^{177,271} both found a tendency toward less bruising and pain with EVLA than with surgery.

In a single-center RCT, de Medeiros and Luccas²⁷² compared EVLA using an 810-nm laser with stripping in 20 patients who had bilateral saphenous incompetence. Each patient served as his or her own control. There was significantly less edema and bruising early after the laser procedure, but at 2 years, no difference was noted in esthetic results, patient satisfaction, or pain, and the authors concluded that midterm results of laser were comparable to surgery.

Vuytsteke et al²⁷³ randomized 164 patients to EVLA (80 patients) or HL/S (84 patients). Patient follow-up lasted an average of 9 months after surgery. The study found shorter duration of postoperative disability after EVLA than after surgical treatment (8.6 vs 22.4 days; $P < .05$).

Kalteis et al²⁷⁴ reported results of a single-center RCT comparing laser ablation (810-nm laser) with stripping of the GSV in 100 patients, including high ligation and phlebectomies performed in both groups. Follow-up was 4 months. Fewer postoperative hematomas occurred in the laser group, but pain and sick leave time after EVLA were longer than after surgery (20 days vs 14 days; $P < .05$). The study concluded that short-term QOL is equal after both procedures but that longer follow-up is needed to decide which is a better choice for the patients.

Pronk et al²⁷⁵ compared HL/S with EVLA using a 980-nm laser energy; 130 legs in 121 patients were randomized. In this study, more pain was noted after EVLA at days 7, 10, and 14 ($P < .01$; $P < .01$; $P = .01$), more

hindrance in mobility at days 7 ($P < .01$) and 10 ($P = .01$), and in self-care ($P = .03$) and daily activities ($P = .01$) at day 7 compared with HL/S. Recurrence at 1 year was similar in the two groups.

Christenson et al²⁵⁰ recently reported 2-year data of an RCT using 980-nm laser for EVLA and compared results with HL/S in 204 randomized patients. Additional phlebectomies or perforator ligations were also performed in both groups. HL/S limbs had significantly more postoperative hematomas than EVLT limbs. Two GSVs in the EVLT group reopened and five partially reopened, but no open GSVs occurred in HL/S limbs. The authors concluded that long-term follow-up is still needed to justify EVLA vs HL/S.

The Committee noted that four of the seven trials had short follow-up and two trials had funding from a commercial company. Overall, the quality of evidence for safety and early efficacy was high, but evidence for long-term effectiveness in these randomized studies was of low quality. Perioperative pain was higher in the EVLA groups in two studies, but postoperative hematomas were less frequent. As also stated by Thakur et al,²⁷⁶ meaningful comparison across randomized studies of endovenous treatments is difficult because of considerable variations in study populations and outcome measures between trials.

Results of RFA. Nicolini²⁷⁷ reported 3-year results after RFA using the first-generation device in 330 limbs and observed a total occlusion rate of 75%, partial occlusion (<5-cm open segment) in 18%, and incomplete occlusion (>5-cm open segment) in 7%. The total occlusion rate in multiple studies using the first-generation device ranged from 75% to 92%, with a partial occlusion rate of between 7% and 26%.^{195,257,278,279}

Long-term results of the Closure Study Group at 5 years after RFA using the same device were published by Merchant et al²⁵⁴ in 2005. The multicenter prospective registry comprised data from >1200 treated limbs. Occlusion rates at 1, 2, and 5 years were 87.1%, 88.2%, and 87.2%, respectively. Duplex ultrasonography identified 185 limbs that had one of the following modes of anatomic failure:

Type I failure (nonocclusion): The treated vein failed to occlude initially and never occluded during the follow-up (12.4%).

Type II failure (recanalization): The vein occluded after treatment but recanalized, partly or completely, at a later time (69.7%).

Type III failure (groin reflux): The vein trunk occluded, but reflux was detected at the groin region, often involving an accessory vein (17.8%).

Relief from symptoms (pain, fatigue, and edema) was noted in most patients; 70% to 80% of those with anatomic failure remained asymptomatic compared with 85% to 94% of those with anatomic success. Type II and type III failures were risk factors for varicose vein recurrence. In addition, catheter pullback speed and body mass index were the two risk factors associated with anatomic failures.

Early results of the new-generation RF catheter were reported by Proebstle et al.²⁶⁰ A prospective, nonrandomized, multicenter study treated 252 GSVs, with an occlusion rate at 6 months of 99.6%. Return to normal daily activities took place on the same day in more than half the patients, with an average time of 1.0 days (standard deviation, 1.9; median, 0 days; range, 0-17 days).

Complications. Serious complications from RFA, such as DVT or thermal skin injury, were not observed in a multicenter, nonrandomized study of RFA using the new-generation RF catheter system.²⁶⁰ Paresthesia occurred in 3.2%, thrombophlebitis in 0.8%, ecchymosis along the course of the GSV in 6.3%, and skin pigmentation in 2%. Lawrence et al²⁶² reported a 2.6% rate of thrombus extension into the femoral veins after 500 RF procedures. No femoral DVT occurred. The rate of proximal thrombus extension was significantly higher in patients with a history of DVT and in those with a GSV diameter of >8 mm ($P < .02$).

RFA vs high ligation, division, and stripping. Four RCTs compared the results of RFA with those of high ligation, division, and stripping.^{195,278,280-282} Rautio et al²⁷⁸ from Finland reported results of a single-center randomized trial in 28 patients. Results at 3 years from the same study were reported later by Perälä et al.²⁸³ This study found significantly less pain with faster recovery and earlier return to work after RFA than after surgery (6.5 days vs 15.6 days). Perioperative costs were higher for RFA (\$794 vs \$360), but total societal costs were lower (\$1401 vs \$1926).

Lurie et al reported results of the Endovenous Radiofrequency Obliteration (Closure procedure) versus Ligation and Stripping (EVOLVEs) study at 4 months¹⁹⁵ and at 2 years.²⁵⁶ This international, multicenter, prospective study randomized 85 patients to RFA or HL/S. The RFA group had faster recovery, less postoperative pain, fewer adverse events, and superior QOL scores ($P < .05$). Clinical and hemodynamic outcomes of RFA were comparable to vein stripping at 2 years. The study found that at 2 years, 91.2% of limbs in the RFA group were free of superficial reflux vs 91.7% in the surgical group ($P = NS$).

Stötter et al²⁸¹ reported results of a single-center RCT from Germany comparing RFA with PIN stripping or cryostripping, with 20 patients in each of the 3 groups. At 1 year, RFA showed significantly better results in QOL and pain assessment, and the authors found significant superiority regarding return to routine activity and work.

Hinchcliffe et al²⁸² reported the results of a single-center trial comparing RFA with open surgery in 16 patients with bilateral recurrent GSV varicose veins after previous bilateral high ligation without stripping. One leg chosen at random was treated with RFA, the other with stripping, and both sides had phlebectomies. The time required to perform RFA was significantly shorter (25 vs 40 minutes), and pain and bruise scores were significantly lower for RFA than for stripping. Follow-up was 1 year. The authors concluded that RFA is the technique of choice to treat the incompetent GSV.

Guideline 11. Endovenous thermal ablation

Guideline No.	11. Endovenous thermal ablation	GRADE of recommendation	Level of evidence
		1. Strong	A. High quality
		2. Weak	B. Moderate quality C. Low or very low quality
11.1	Endovenous thermal ablations (laser and radiofrequency ablations) are safe and effective, and we recommend them for treatment of saphenous incompetence.	1	B
11.2	Because of reduced convalescence and less pain and morbidity, we recommend endovenous thermal ablation of the incompetent saphenous vein over open surgery.	1	B

The Committee noted that these studies had short-term to medium-term follow-up, 1 year in two studies, 2 years in one study, and 3 years in the fourth study. RFA treatment resulted in faster return to work and normal activities, higher patient satisfaction, less pain, and better short-term QOL scores, with high-quality evidence confirming early efficacy and safety. The studies, however, did not report bias protection measures; therefore, the evidence of midterm efficacy is of low quality and no evidence is available on long-term efficacy.

Radiofrequency ablation vs endovenous laser ablation. Four RCTs compared RFA with EVLA.^{255,280,284-286} Morrison²⁵⁵ reported a single-center randomized trial performed in 50 patients with bilateral GSV reflux. One limb was treated with RFA and the other with EVLA. The saphenous occlusion rate was 80% with RFA and 66% with EVLA ($P = \text{NS}$), and there was no difference in early complication rates.

In the prospective, industry-sponsored, multicenter Radiofrequency Endovenous ClosureFAST versus Laser Ablation for the Treatment of Great Saphenous Reflux: A Multicenter, Single-blinded, Randomized Study (RECOVERY) trial, Almeida et al²⁸⁶ randomized 87 limbs to treatment with RF catheter or 980-nm EVLA. There were no major complications. All scores referable to pain, ecchymosis, and tenderness were statistically lower in the catheter group at 48 hours, 1 week, and 2 weeks. Minor complications were more prevalent in the EVLA group ($P = .02$). VCSS and QOL measures were lower in the catheter group at all evaluations.²⁸⁶

In a similar trial, Shepherd et al²⁸⁵ randomized 131 patients to treatment with a new-generation RF catheter or 980-nm EVLA. Perioperative pain was less after RFA than after laser, but clinical and QOL improvements were similar in both groups at 6 weeks.

A recent RCT by Gale et al²⁸⁴ compared results of 810-nm wavelength laser with RFA. All veins were closed at 1 week after the procedure. The recanalization rate at 1 year was significantly higher in the RF group (ClosureFAST system) than after laser (11 of 48 vs 2 of 46, $P = .002$). The mean VCSS score change from baseline to 1 week postpro-

cedure was higher for RFA than EVLA ($P = .002$), but there was no difference between groups at 1 month ($P = .07$) and 1 year ($P = .9$). The authors concluded that both methods of endovenous ablation effectively reduce symptoms of superficial venous insufficiency. EVLA was associated with greater bruising and discomfort in the perioperative period but may provide a more secure long-term closure than RFA.

The Committee noted that the data support less bruising and less pain with the new RF catheter system than with the 980-nm EVLA. However, further trials with higher-wavelength EVLA, as well as with long-term follow-up, are needed before any conclusion on the use of any EVLA vs RFA can be made.

Hemodynamic improvement after saphenous ablations. In a comparative nonrandomized study, Marston et al²⁸⁷ observed both hemodynamic and clinical improvement in patients treated by either RFA or laser. These authors reported significant improvements in venous filling time and in VCSS, with no differences between the groups.

Sclerotherapy

Injection of a chemical into the vein to achieve endoluminal fibrosis and obstruction of the vein has been used for almost a century.²⁸⁸ Sigg et al,^{289,290} Fegan et al,^{291,292} Tournay,²⁹³ and Wallois²⁹⁴ are considered the pioneers of liquid sclerotherapy, whereas Hobbs²⁹⁵ was the first to provide scientific evidence on the clinical outcome after sclerotherapy compared with surgery. Sclerotherapy in some European countries, especially in France, has been a very popular treatment for varicose veins.²⁹⁶⁻²⁹⁹ Although liquid sclerotherapy has been used primarily for obliteration of spider veins or telangiectasia (veins ≤ 3 mm in diameter), interest in the use of sclerotherapy greatly increased when Cabrera et al³⁰⁰ reported in 1995 that foam prepared by mixing a “physiologic gas” with the detergent polidocanol was effective for obstruction of larger veins. Ultrasonographically guided foam sclerotherapy has rapidly spread for treatment of primary and recurrent varicose veins, including the GSV and SSV, perforating veins, and venous malformations.³⁰¹⁻³¹¹

Table VII. Sclerosing agent comparison

<i>Agent</i>	<i>Manufacturer</i>	<i>Category</i>	<i>FDA approval</i>	<i>Strength</i>	<i>Advantages</i>	<i>Disadvantages</i>
Hypertonic saline	Multiple	Osmotic	Off-label usage	+ +	Low risk of allergic reaction; wide availability; rapid response	Off label; painful to inject; hyperpigmentation; necrosis; rapid dilution; not recommended for facial veins
Sclerodex (hypertonic saline and dextrose)	Omega Laboratories, Montreal, Quebec	Osmotic	Not approved	+ +	Low risk of allergic reaction; low risk of necrosis; high viscosity	Not FDA-approved; stings when injected; hyperpigmentation
Chromex (72% chromated glycerin)	Omega Laboratories, Montreal, Quebec	Alcohol agent	Not approved	+	Low incidence of hyperpigmentation, necrosis, and allergic reaction	Not FDA-approved; weak sclerosing agent; highly viscous and painful to inject; may cause hematuria at high doses
Nonchromated glycerin	Compounded at pharmacy	Alcohol agent	Off-label usage	+	Low incidence of hyperpigmentation, necrosis, and allergic reaction	Weak sclerosing agent; typically only used for telangiectasia
Scleromate (morrhuate sodium)	Glenwood, LLC, Englewood, New Jersey	Detergent	Approved	+ + +	FDA-approved	High incidence of skin necrosis and anaphylaxis
Sotradecol (sodium tetradecyl sulfate)	Bioniche Pharma USA, Lake Forest, Ill (distributed by AngioDynamics Inc, Queensboro, NY)	Detergent	Approved	+ + + + +	FDA-approved; low risk of allergic reaction; potent sclerosant	Potential necrosis with extravasation; telangiectasia matting

FDA, Food and Drug Administration.

Sclerosing agents. The mechanisms of action of sclerosing solutions are the destruction of venous endothelial cells, exposure of subendothelial collagen fibers, and ultimately, the formation of a fibrotic obstruction. The higher the concentration of the solution and the smaller the vein, the greater the endothelial damage. Delivery of the solution as a foam prolongs the time of contact and amplifies the effect of the chemical. In the United States, current FDA-approved agents for sclerotherapy include sodium tetradecyl sulfate (STS), polidocanol, sodium morrhuate, and glycerin, which is usually used with epinephrine. Hypertonic saline, although not approved for sclerotherapy in the United States, has also been used for many years (Table VII).

Osmotic agents. Hypertonic saline is a weak hyperosmolar sclerosing agent that causes dehydration of endothelial cells through osmosis, which leads to endothelial cell death. The usual concentration is used in 23.4% sodium chloride. One formulation is manufactured as Sclerodex (Omega Laboratories Ltd, Montreal, Quebec, Canada). Burning pain is frequent during injection. Extravasation may cause skin ulcers and tissue necrosis, and osmotic agents are used for occlusion of small veins only.

Detergents. Detergents destroy the endothelium by denaturation of the cell surface proteins. STS (as Sotradecol,

Bioniche Pharma USA, Lake Forest, Ill; Fibro-Vein, STD Pharmaceutical Products Ltd, Hereford, UK; Tromboject, Omega Laboratories) is a long-chain fatty alcohol. A critical micellar concentration is needed to cause endothelial cell injury, and repeated treatments are frequently desirable. The solution is safe and painless when injected. When the solution is injected in higher concentration, extravasation may result in tissue necrosis. Hyperpigmentation, matting, and allergic reactions have been described. Foaming of this agent is easy and will result in longer exposure of the agent to the vein wall using a smaller amount of the solution.

Polidocanol (Asclera injection, Bioform Medical Inc, San Mateo, Calif), another detergent, was approved for use in the United States in 2010. This is the most commonly used sclerotherapy agent in the world; it is safe and painless when injected, with a low risk of tissue necrosis when used in a low concentration. It may cause hyperpigmentation, but has a very low rate of allergic or anaphylactic reaction.

Morrhuate sodium (Scleromate, Glenwood, LLC, Englewood, NJ) is a detergent that is used less frequently because of the relatively higher incidence of skin necrosis observed with extravasation and because of the higher risk of anaphylactic reactions.

Table VIII. Indications and concentrations of sclerosing agents

Indications	STS	Polidocanol
Varicose veins <8 mm	0.5%-3.0%	1%-3% ^a
Reticular veins 2-4 mm	0.25%-0.5%	0.6%-1.0%
Telangiectasias 0.1-2.0 mm	0.125%-0.25%	0.25%-0.6%

STS, Sodium tetradecyl sulfate.

^aNot approved for varicose veins in the United States.

Alcohol agents. Alcohol agents are weak sclerosants that cause irreversible endothelial damage by contact. Glycerin is a corrosive agent that destroys the cell surface proteins by affecting chemical bonds. Chromated glycerin is used most frequently as a solution of glycerin, sterile water, and benzyl alcohol (Chromex, Omega Laboratory). It is not approved in the United States. It is usually mixed with 1% lidocaine and epinephrine. Chromated glycerin is safe and rarely leads to tissue necrosis, hyperpigmentation, or allergy. Suitable for treatment of small veins or telangiectasia, it may cause hematuria when used in a higher concentration.

Liquid sclerotherapy. The sclerosing chemicals need to be diluted before use, and the concentration of the solution should be the lowest when used for treatment of very small diameter veins, such as telangiectasia. Recommended concentrations of STS and polidocanol are listed in Table VIII.

Liquid sclerotherapy is performed using small tuberculin syringes and a 30- or 32-gauge needle. Treatment is usually started with larger varicose veins and ends with reticular veins and telangiectasia. The proximal part of the limb is treated first and the distal part second. Using loupes for magnification and transillumination (Veinlite, Trans-Lite, Sugar Land, Tex; VeinViewer, Luminex, Memphis, Tenn) helps intraluminal injection and avoids extravasation of the drug. The injection maximum of 1.0 mL of the chemical to one site is recommended, with not more than 10 to 20 injections performed per session. Severe pain during injection may signal extravasation, and further injection should be avoided.²⁹ Gauze pads are placed on the injection sites, and the patient is instructed to wear 30 to 40 mm Hg graduated compression stockings for 1 to 3 days after treatment of telangiectasia and reticular veins and at least 1 week after treatment of varicose and perforating veins.

Foam sclerotherapy. Foam sclerotherapy of the saphenous vein is the least invasive of the endovenous ablation techniques. The European Consensus Meetings on Foam Sclerotherapy^{308,309} reported that foam was an effective, safe, and minimally invasive endovenous treatment for varicose veins with a low rate of complications.

The most popular technique used today was developed by Tessari et al³¹² using a three-way stopcock connected with two syringes. Experts recommend a ratio of 1 part solution of STS or polidocanol to 4 or 5 parts of air.³¹³ Mixing the drug with air using the two syringes and push-

ing the mixture from one syringe into the other 20 times results in an approximate bubble size of <100 μm.

Coleridge-Smith³⁰⁶ advises to cannulate the veins in supine patients and then elevate the limb 30° to inject the foam. Ultrasonography is used to monitor the movement of foam in the veins. The saphenous trunk is injected first, followed by varicose and perforating veins if indicated. A maximum of 20 mL of foam is injected during one session. Bergan³¹³ recommends elevation of the limb for 10 to 15 minutes after injection to minimize the volume of foam that gets into the systemic circulation. The procedure is completed by placing a short stretch bandage or 30 to 40 mm Hg graduated compression stockings (or both) on the limb. Although most authors recommend 1 to 2 weeks of compression,^{313,314} a recent RCT found no advantage to compression bandaging for >24 hours when thromboembolus-deterrent stockings were worn for the remainder of 14 days.³¹⁵

Complications. Severe complications after sclerotherapy, such as death, anaphylactic reaction, pulmonary emboli, stroke, and large areas of skin necrosis, are very rare (<0.01%).³¹⁶ Severe but rare complications also include thrombophlebitis, nerve damage (saphenous, sural), DVT, or inadvertent arterial injection of the solution.^{317,318} Transient neurologic adverse effects such as visual disturbance, migraine-like headache, or confusional state may occur and are more frequent in patients with a patent foramen ovale.³¹⁹

Most complications are minor, and include matting, pigmentation, pain, allergy, and skin urticaria. The higher the concentration of the agent, the higher the likelihood of hyperpigmentation, a minor complication that can be observed in up to 30% of the cases.³²⁰ Between 70% and 95% of the pigmentations, however, resolve by 1 year after therapy.³¹⁷

The incidence of major neurologic events after foam injection is rare; instances of stroke were reported by Bush et al³²¹ and others.^{319,322,323} Immediate treatment with 100% oxygen and possibly hyperbaric oxygen therapy should be considered. Factors implicated in the risk of stroke after foam sclerotherapy include the use of air instead of carbon dioxide to prepare the foam, large bubble size, a patent foramen ovale, failure to elevate the limb after treatment, prolonged immobility after therapy, and an excessive amount of foam used during one session.^{319,322-324} Standardization of the bubble size using commercially prepared microfoam and the replacement of air with carbon dioxide in the solution may decrease the risk of neurologic complications.³²⁵

A recent study Regan et al³²⁶ proposed that the composition and properties of the foam, including bubble size and gaseous components, may indeed contribute to the potential for microcirculatory obstruction and cerebral ischemia. The authors tested an ultralow nitrogen polidocanol endovenous microfoam with controlled bubble size and density and found that patients treated with foamed liquid sclerosants are commonly exposed to cerebrovascular gas bubbles. In a series of 60 high-risk patients with

middle cerebral artery bubble emboli during or after treatment, however, there was no evidence of cerebral or cardiac microinfarction.

Although rare, allergic reactions and anaphylaxis after injection of a sclerosing solution can occur, and it is essential to have an emergency protocol, resuscitation equipment, oxygen, and drugs (diphenhydramine, epinephrine, cimetidine, steroids) available to prevent a major catastrophe.

Guex et al²⁹⁶ reported early and midterm complications in a prospective multicenter registry that included 12,173 sclerotherapy sessions, consisting of 5434 with liquid, 6395 with foam, and 344 using both. Ultrasonographic guidance was used in 4088 sessions (33.9%), and 49 incidents or accidents (0.4%) occurred, of which 12 were with liquid and 37 with foam. There were 20 cases of visual disturbances, in 19 cases, foam or air block was used; all resolved shortly, without any after effects. A femoral vein thrombosis was the only severe adverse event in this study, which also demonstrated that sclerotherapy is a safe technique.

A systematic review of foam sclerotherapy also found a low rate of major complications.¹⁰ In >9000 patients studied, the median rates of serious adverse events, including PE and DVT, were rare, <1%. The median rate of visual disturbance was 1.4%, headache occurred in 4.2%, thrombophlebitis in 4.7%, matting, skin staining, or pigmentation in 17.8%, and pain at the site of injection in 25.6%.

Morrison et al³²⁷ evaluated the safety of carbon dioxide in patients undergoing 1% polidocanol foam sclerotherapy and compared them with a historical control of patients who had air mixed with the sclerosing agent. The carbon dioxide-based foam group had 128 patients (115 women and 13 men). Visual disturbances were experienced by 3.1% (4 of 128) of the carbon dioxide group and in 8.2% (4 of 49) of the air group ($P = .15$). The incidence of chest tightness (3.1% vs 18%), dry cough (1.6% vs 16%), and dizziness (3.1% vs 12%) was significantly lower in the carbon dioxide group compared with the air group ($P < .02$). Nausea occurred in 2% of the carbon dioxide foam group and in 4% of the air foam group ($P = .53$). Overall, the proportion of patients describing adverse effects decreased from 39% (19 to 49) to 11% (14 to 128) as carbon dioxide replaced air for foam preparation ($P < .001$). The authors concluded that adverse effects decreased significantly if carbon dioxide rather than air was used to make the sclerosing foam for chemical ablation of superficial veins of the lower extremity.

Results. Short-term and midterm results of liquid sclerotherapy have been good for both reticular and varicose veins, but durable success depends largely on the presence or absence of axial reflux. Those with untreated incompetent saphenous veins have the highest rate of recurrence.^{295,328} Kern et al³²⁹ reported results of liquid sclerotherapy of telangiectasia and reticular veins in 96 patients. Those who wore elastic stockings for 3 weeks after treatment had an early success rate of 76%. Goldman³³⁰ published results of a prospective trial comparing the effi-

cacy of two liquid sclerosants, polidocanol and STS, and both were used to treat varicose and telangiectatic veins. All patients had an average of 70% improvement, and 70% to 72% were satisfied in all vein categories treated with either solution.

Liquid sclerotherapy does poorly for treatment of the incompetent GSV, but results of foam sclerotherapy are much more encouraging. Rabe et al³³¹ performed a multicenter RCT to evaluate the efficacy and safety of GSV sclerotherapy using standardized polidocanol foam. The 3% foam was more efficient than and equally as safe as the 3% liquid for the treatment of the incompetent GSV.

In a prospective comparative study, Yamaki et al³³² compared results of duplex-guided foam sclerotherapy and duplex-guided liquid sclerotherapy in 77 patients. Duplex scanning at 1 year demonstrated complete occlusion in the GSV for duplex-guided foam sclerotherapy in 25 limbs (67.6%), which was a significantly higher rate than that for duplex-guided liquid sclerotherapy in 7 limbs (17.5%; $P < .0001$). Recurrent varicose veins were found in 3 patients (8.1%) in the duplex-guided foam sclerotherapy group and in 10 (25%) in the duplex-guided liquid sclerotherapy group at 1 year ($P = .048$). Cabrera et al³³³ reported an 80% occlusion rate at 4 to 6 years when they used microfoam to treat incompetent GSV in 415 limbs.

In 808 patients with 1411 affected limbs, Coleridge Smith³⁰⁶ used 1% polidocanol, 1% STS, and 3% STS in the form of foam to treat incompetent saphenous trunks, and 459 limbs were available for duplex imaging at a follow-up of ≥ 6 months. The GSV remained obliterated in 88% of limbs and the SSV in 82%.

A Cochrane review on sclerotherapy published by Tisi et al⁴⁰ in 2006 concluded that evidence supports the current place of sclerotherapy in modern clinical practice, which is usually limited to treatment of recurrent varicose veins after surgery and thread veins.

The efficacy of foam sclerotherapy on QOL was recently demonstrated in a single-center cohort study by Darvall et al.³³⁴ These authors found that ultrasound-guided foam sclerotherapy for great and small saphenous varicose veins leads to significant improvements in generic and disease-specific health related QOL for at least 12 months after treatment.

Surgery vs sclerotherapy. A Cochrane review in 2004 examined results of surgery vs sclerotherapy for the treatment of varicose veins. Rigby et al³³⁵ reviewed 2306 references that included 61 comparative studies and 9 randomized trials. The study observed a trend that sclerotherapy was better at 1 year and surgery had a better outcome at 3 to 5 years. The meta-analysis concluded, however, that there was insufficient evidence to preferentially recommend sclerotherapy for treatment of varicose veins over surgical treatment.

Wright et al³²⁵ reported the effect of polidocanol microfoam and compared its use with surgery or sclerotherapy in the management of varicose veins. This European RCT found that 1% microfoam was inferior to surgery but supe-

Guideline 12. Sclerotherapy of varicose veins

Guideline No.	12. Sclerotherapy of varicose veins	GRADE of recommendation	Level of evidence
		1. Strong	A. High quality
		2. Weak	B. Moderate quality C. Low or very low quality
12.1	We recommend liquid or foam sclerotherapy for telangiectasia, reticular veins, and varicose veins.	1	B
12.2	For treatment of the incompetent saphenous vein, we recommend endovenous thermal ablation over chemical ablation with foam.	1	B

rior to conventional sclerotherapy. Foam resulted in less pain and earlier returns to work than surgery.

In a systematic review on foam sclerotherapy, Jia et al¹⁰ analyzed data of 69 studies, including 10 RCTs. All patients underwent foam sclerotherapy for varicose veins, most frequently with use of polidocanol to ablate the GSV or SSV. The median rate of complete occlusion of treated veins was 87%. Meta-analysis for complete occlusion suggested that foam sclerotherapy was less effective than surgery (RR, 0.86; 95% CI, 0.67-1.10) but more effective than liquid sclerotherapy (RR, 1.39; 95% CI, 0.91-2.11), although there was substantial heterogeneity between studies. The authors concluded that there is currently insufficient evidence to allow a meaningful comparison of the effectiveness of this treatment with that of other minimally invasive therapies or surgery.

Surgery vs endothermal ablations vs foam sclerotherapy. A systematic review and meta-analysis of RFA, EVLA, and foam sclerotherapy for primary varicose veins was reported by Luebke and Brunkwall⁹ in 2008. Results were compared with those achieved with conventional ligation and vein stripping. This study included 29 EVLA studies, 32 RFA studies, and 22 foam sclerotherapy trials. RFA was inferior to EVLA and foam sclerotherapy in saphenous occlusion rate, phlebitis, DVT, and paresthesias. EVLA had the highest occlusion rate and least recurrence compared with RFA and foam. Foam sclerotherapy of varicose veins was associated with a higher recurrence rate in patients with saphenofemoral incompetence compared with the rates after EVLA or RFA. This study concluded that EVLA, RFA, and foam sclerotherapy seem to be safe and effective, with good short-term and midterm results, but large, high-quality, prospective RCTs comparing endovenous techniques and endovenous techniques with surgery are needed before considering endovenous techniques as the standard treatment of varicose veins.

In a subsequent meta-analysis of EVLA results, van den Bos et al²⁴⁸ compared RFA, foam sclerotherapy, and HL/S. They analyzed results of 64 clinical trials that included treatment of 12,320 limbs with an average follow-up of 32.2 months. The estimated pooled success rate at 3 years was highest after EVLA (94%), followed by RFA (84%), HL/S (78%), and foam sclerotherapy (77%). EVLA

was significantly superior to other treatment modalities in abolition of the saphenous reflux. Foam therapy and RFA were equally effective as surgery. The meta-analysis concluded that endovenous thermal ablations or foam sclerotherapy is at least as effective as surgery for treatment of varicose veins.

Another large meta-analysis of the SVS and AVF on varicose vein treatment is reported by Murad et al¹² in this issue the *Journal of Vascular Surgery*. The authors examined data from 8207 patients reported in 38 comparative studies that included 29 RCTs. Each study included two or more treatments, such as surgery, laser ablation, RFA, and liquid or foam sclerotherapy. The meta-analysis found that surgery was associated only with a nonsignificant reduction in varicose vein recurrence, compared with sclerotherapy, laser therapy, or RFA. Studies of laser therapy, RFA, and foam sclerotherapy, however, demonstrated short-term effectiveness and safety. The authors concluded that low-quality evidence supports long-term safety and efficacy of surgery for the treatment of varicose veins and that short-term studies support the efficacy of less invasive treatments, which are associated with less early disability and pain.

Results of these meta-analyses and data of several RCTs and single-treatment cohort studies as well as a recent review³³⁶ and an editorial³³⁷ now question the continuing role of open surgery with HL/S as the gold standard for treatment of varicose veins. On the basis of the available data, the Joint Committee of the SVS/AVF agreed that because of the minimally invasive nature and similar or better early-term and equivalent midterm results, endovenous thermal ablations should be recommended over open surgery as the first line of treatment of varicose veins associated with axial reflux. The Committee also recognized that results of foam therapy have improved but that they are not yet equivalent to those obtained after endovascular or open venous surgery. The Committee recommended that there was an urgent need for well-performed, large RCTs comparing adverse effects and long-term saphenous occlusion rates of surgery, endovenous thermal ablations, and foam sclerotherapy. These studies should include detailed analyses of safety and costs and should also evaluate the QOL of patients who undergo treatment using any of these procedures.

SPECIAL VENOUS PROBLEMS**Perforating veins**

An association between incompetent perforating veins and venous ulcers was established more than a century ago by Gay,³³⁸ and surgical perforator interruption was recommended to treat venous ulcers by Homans,³³⁹ Linton,³⁴⁰ Cockett et al,^{341,342} and Dodd.³⁴³ Hauer³⁴⁴ introduced SEPS in 1985, O'Donnell³⁴⁵ was the first to use laparoscopic instrumentation, while the Mayo Clinic team³⁴⁶ and Conrad³⁴⁷ improved the technique and added carbon dioxide insufflation to the procedure. Between 1992 and 2008, SEPS became the technique of choice for perforator ablation, primarily because of the reduced rate of wound complications.^{62,348-350}

However, the emergence of ultrasonographically guided thermal ablations and sclerotherapy in recent years has transformed the techniques of perforator ablation.³⁵¹⁻³⁵⁶ Advantages of percutaneous ablation of perforators (PAPS) include the low risk of a minimally invasive procedure that is easily repeatable and can be performed under local anesthesia in an office setting.³⁵⁷

Techniques of perforator ablation

Subfascial endoscopic perforator vein surgery. SEPS is performed under general or epidural anesthesia. The single or the double endoscopic port techniques can be used for dissection and division of medial calf perforators.^{62,348-350} Most authors use balloon dissection and carbon dioxide insufflation with a pressure of 30 mm Hg and a pneumatic thigh tourniquet inflated to 300 mm Hg to avoid any bleeding in the surgical field.³⁵⁸ Division of the fascia of the deep posterior compartment with a paratibial fasciotomy is required to identify all important medial perforating veins. Occlusion of the perforators can be done with endoscopic clips, although most surgeons use an ultrasonic harmonic scalpel for division and transection of the perforators. The wounds are closed, the tourniquet is deflated, and the extremity is wrapped with an elastic bandage. The operation is an outpatient procedure, and patients are encouraged to ambulate 3 hours after the operation.

Percutaneous ablation of perforators. PAPS is performed under ultrasound guidance, with direct needle puncture of the perforating vein. Local anesthesia is used, with the patient in the reversed Trendelenburg position to allow for full venous distention. The tip of the needle should be at or just below the fascia in the vein to minimize deep vessel and nerve injury.

Radiofrequency ablation. The ClosureRFS Stylet is a new intravascular ablation device (VNUS Medical Technologies, San Jose, Calif) available for RFA of the perforating vein. Intraluminal placement of the RF stylet is confirmed by ultrasonography and also by measuring impedance: values between 150 and 350 ohms indicate the intravascular location of the tip of the probe. Local anesthesia is used to infiltrate the tissues around the stylet before treatment, and the patient is then placed in the Trendelenburg position. Treatment is performed with a target tem-

perature of 85°C. All four quadrants of the vein wall are treated for 1 minute each. The catheter is then withdrawn 1 or 2 mm, and a second treatment is performed. The treatment is finished with applying compression to the region of the treated perforating vein.

Endovenous laser ablation. For laser treatment of perforating veins, a 16-gauge angiocatheter (for a 600- μ m laser fiber) or a 21-gauge micropuncture needle (for a 400- μ m laser fiber) can be used.³⁵⁷ Intraluminal placement of the access catheter is confirmed by ultrasonography and by aspiration of blood at or just below the fascial level. Once the fiber is positioned in the vein at or just below the level of the fascia, local anesthesia is infiltrated, and various methods of energy application are used. Elias³⁵⁷ recommends a pulsed technique with the generator set for 15 watts and a 4-second pulse interval. Each segment of vein is treated twice, thus giving 120 J to each segment. Three segments are usually treated. Proebstle and Herdemann³⁵⁹ also treat the perforating veins at three locations, each segment receiving between 60 and 100 J. The rest of the procedure is similar to RFA.

Sclerotherapy. For chemical ablation of perforating veins, a 25-, 27-, or 30-gauge needle can be used for cannulation. If the anatomy allows, a wire may be placed into the deep system for better control of the access. Ultrasonographically guided sclerotherapy has been reported using morrhuate sodium,³⁵¹ although most experts recommend STS or polidocanol foam. Care should be taken to avoid injection of the agent into the accompanying artery. During injection of 0.5 to 1 mL of the sclerosant, the patient's leg is elevated to avoid flow into the deep system. After treatment, compression is applied over the treated perforators.³⁵⁷

Complications. SEPS is safe and complications are rare. Death or PE has not been reported, and the North American SEPS registry had no patient with DVT \leq 30 days of the procedure. Wound infection and saphenous neuralgia occurred in 6% each. In an RCT, Pierik et al³⁶⁰ observed a significantly higher rate of wound complications after open perforator ligation, using a modified Linton procedure, than after endoscopic perforator ligation (53% vs 0%; $P < .001$).

Complications after PAPS are rare, and in a review of published series, O'Donnell³⁵⁶ found evidence of tibial vein DVT in three series and foot drop and skin burn in one each. Masuda et al³⁵¹ treated 80 limbs with sclerotherapy of the perforating veins. There were no cases of DVT involving the deep vein adjacent to the perforator injected. One patient had skin complications with skin necrosis.

Results of perforator ablation

Subfascial endoscopic perforator vein surgery. Most series of SEPS were performed in patients with advanced disease (class C₃-C₆, mostly C₅ and C₆), and perforator interruption was performed with ablation of the incompetent superficial system. Therefore, benefit directly attributable to perforator interruption is not well known.

Simple varicose veins (CEAP class C₂). In an RCT, Kianifard et al³⁶¹ analyzed the benefits of adding SEPS to saphenofemoral ligation and stripping of the GSV in patients with class C₂ disease. The study allocated 38 to the SEPS group and 34 to the no-SEPS group. The two groups were similar with respect to pain, mobility, varicose vein recurrence, and QOL scores during the 1-year follow-up. A significantly higher proportion of patients in the no-SEPS group had incompetent perforating veins on duplex imaging at 1 year (25 of 32 vs 12 of 38; $P < .001$). This RCT concluded that at 1 year in class C₂ patients, no additional clinical benefit could be observed when SEPS was added to HL/S.

This finding was supported by a prospective study by van Neer et al³⁶² in 62 limbs with class C₂ disease, who had varicose veins distal to the knee and underwent HL/S of the GSV to the level of the knee. Clinical and ultrasonographic residual varicose veins at 6 months were not significantly related to the presence of preoperative incompetent perforating veins.

Chronic venous insufficiency (CEAP class C₃-C₆). The North American SEPS registry reported the results of SEPS performed in 17 U.S. centers on 155 limbs, 85% with class C₅ and C₆ disease. Ulcer healing at 1 year was 88%, with the median time to ulcer healing of 54 days.^{62,350} Ulcer recurrence was 16% at 1 year and 28% at 2 years. This registry contained data on 27 patients with class C₆ disease who underwent SEPS alone. The ulcer recurrence rate (35%) in the SEPS-only group at 2 years was not significantly higher than recurrence in patients who underwent SEPS and superficial ablation alone (25%).

Nelzen³⁶³ prospectively collected data from 149 SEPS procedures in 138 patients, of whom 89% underwent saphenous surgery as well. During a median follow-up of 32 months, 32 of 36 ulcers healed, more than half (19 of 36) ≤ 1 month. Three ulcers recurred, one of which subsequently healed during follow-up. In a subsequent series from the same group, 97 limbs with class C₅ and C₆ disease were treated with SEPS. Superficial ablation was also performed in 87%. All patients were monitored for at least 5 years. Ulcers healed in 87%, and the 3- and 5-year recurrence rates were 8% and 18%. Long-term data in 51 limbs with class C₅ and C₆ disease were published by Iafrati et al,³⁶⁴ who performed SEPS alone in 23 limbs and SEPS with stripping in 28. The ulcers healed rapidly, and the 5-year ulcer recurrence rate was low (13%).

Post-thrombotic patients do worse than those with primary incompetence. In the Mayo Clinic series, 5-year ulcer recurrence was 56% in post-thrombotic patients vs 15% in patients with primary valvular incompetence ($P < .05$).^{365,366} Post-thrombotic patients with significant deep venous disease still gained some benefit, as measured by improved VCSS as well as an apparent ease in treating the smaller and more superficial ulcers compared with their preoperative state.

A single-center cohort study by Bianchi et al³⁶⁷ observed ulcer healing in 91% (53 of 58) of limbs with C₆ disease at a mean of 2.9 months (range, 13 days-17 months) after SEPS and saphenous stripping. Ulcer recur-

rence at 30 months was 6%. Ulcer recurrence at 4 years was as high as 31% in the ESCHAR study when compression treatment was combined with surgical ablation of the superficial reflux, but no perforator interruption was performed.¹⁵⁷

In a large, retrospective, multicenter cohort study, Tawes et al³⁶⁸ monitored 832 patients with CEAP clinical class C₄ to C₆ for 9 years after SEPS. Only 55% of the patients underwent HL/S in addition to SEPS. In this study, 92% of ulcers healed with only 4% recurrences. There was a 3% nonfatal complication rate, and significant improvement was documented in venous hemodynamics in a subset of patients.

In a systematic review, Tenbrook et al³⁸ reported results of the SEPS procedure performed with or without superficial ablation on 1140 limbs in 1 RCT and 19 case series. Ulcers in 88% of limbs healed and recurred in 13%, at a mean time of 21 months. Risk factors for nonhealing and recurrence included postoperative incompetent perforating veins, pathophysiologic obstruction, previous DVT, and ulcer diameter > 2 cm. The authors concluded that surgical treatment, including SEPS, with or without saphenous ablation, is recommended for patients with venous ulcers, but RCTs are needed to discern the contributions of compression therapy, superficial venous surgery, and SEPS in patients with advanced CVI.

The Dutch SEPS RCT⁵⁹ compared results of surgical treatment in 103 patients (SEPS, with or without superficial reflux ablation) with medical treatment in 97 patients with venous ulcers. The rate of ulcer healing at 29 months in the surgical group was 83%, with recurrence of 22%. In the conservative treatment group, ulcers healed in 73% and recurred in 23% ($P = \text{NS}$). The study concluded that SEPS, with or without superficial ablation, failed to improve healing or recurrence over best medical treatment. Ulcer size and duration were independent factors adversely affecting ulcer healing and recurrence. In a subgroup analysis, medial ulcers, recurrent ulcers, or SEPS done in centers of excellence did show significant benefit. In this study, 86% of the patients had medial or recurrent ulcers. On the basis of these data and results of a previous RCT by Stacey et al,³⁶⁹ the evidence summary of O'Donnell¹⁹ concluded that further properly conducted RCTs are needed to provide high-quality evidence of efficacy of perforator interruptions in patients with leg ulcers. Previous AVF recommendations agreed with this statement.³⁷⁰

A recent meta-analysis of SEPS by Luebke and Brunkwall³² reviewed data of studies published between 1985 and 2008 and concluded that SEPS, used as part of a treatment regimen for severe CVI, benefits most patients in the short-term regarding ulcer healing and the prevention of ulcer recurrence. SEPS is safe and has less early postoperative complications compared with the classic Linton procedure. Luebke and Brunkwall also concluded that further prospective RCTs are needed to define the long-term benefits of SEPS.

Hemodynamic improvement after SEPS with superficial ablation was confirmed by Padberg et al,¹²⁷ who per-

Guideline 13. Treatment of perforating veins

Guideline No.	13. Treatment of perforating veins	GRADE of recommendation	Level of evidence
		1. Strong	A. High quality
		2. Weak	B. Moderate quality C. Low or very low quality
13.1	We recommend against selective treatment of incompetent perforating veins in patients with simple varicose veins (CEAP class C ₂).	1	B
13.2	We suggest treatment of "pathologic" perforating veins that includes those with outward flow of ≥ 500 -ms duration, with a diameter of ≥ 3.5 mm, located beneath healed or open venous ulcer (class C ₅ -C ₆).	2	B
13.3	For treatment of "pathologic" perforating veins, we suggest subfascial endoscopic perforating vein surgery, ultrasonographically guided sclerotherapy, or thermal ablations.	2	C

formed superficial and perforator ablations in 11 limbs and used air plethysmography, foot volumetry, and duplex scanning to assess results. At a median follow-up of 66 months, expulsion fraction and half-refilling time had both improved significantly in patients, with no ulcer recurrence. Rhodes et al,⁹⁵ from Mayo Clinic, used strain-gauge plethysmography to quantitate calf muscle pump function and venous incompetence before and after SEPS. Significant improvement was noted in both calf muscle pump function and venous incompetence in 31 limbs studied ≤ 6 months after SEPS. Saphenous stripping was done in addition to SEPS in 24 of the 31 limbs. Although the seven limbs undergoing SEPS alone had significant clinical benefits, the hemodynamic improvements were not statistically significant. It is important to note also that Akesson et al³⁷¹ failed to show additional benefit in ambulatory venous pressure, when perforator interruption was performed after saphenous vein ablation.

Percutaneous ablation of perforators. PAPS is a new technique, and most publications had a small number of patients with short follow-up, who were treated frequently for mild disease (CEAP class C₂-C₃).³⁵⁷ Most data provided are on safety and surrogate end points such as perforating vein occlusions but less so on clinical and functional end points. A systematic review of five recently published cohort studies and seven unpublished case series by O'Donnell³⁵⁶ found a mean occlusion rate of 80% and a mean follow-up of < 2 months.

Ultrasonographically guided sclerotherapy is gaining rapid acceptance because perforating veins can be accessed easily with a small needle without much pain to the patient. Masuda et al³⁵¹ reported clinical results with ultrasonographically guided sclerotherapy using morrhuate sodium in 80 limbs with predominantly perforator incompetence alone. The authors noticed a significant improvement in VCSS, and ulcers rapidly healed in 86.5%, with a mean time to heal of 36 days. The ulcer recurrence rate was 32% at a mean of 20 months despite low compliance (15%) with compression hose. New and recurrent perforators were identified in 33% of limbs, and ulcer recurrence was statis-

tically associated with perforator recurrence as well as presence of postthrombotic syndrome.

Conclusions. Current data do not support adding perforator ablation to ablation of the superficial system in patients with simple varicose veins,^{361,362} and the Committee recommends against treatment of perforators in patients with CEAP class C₂ disease (GRADE 1B). In patients with advanced CVI, current data provide moderate evidence that large (≥ 3.5 mm), high-volume, incompetent "pathologic" perforators (reflux ≥ 500 ms), located in the affected area of the limb with outward flow on duplex scanning in patients with class C₅ or C₆ disease, can be treated by experienced interventionists, unless the deep veins are obstructed (GRADE 2B).^{22,56,87} Clinical data on the efficacy of perforator ablations were obtained primarily by using the SEPS procedure, but ultrasonographically guided sclerotherapy or thermal ablations, when performed with similar low complication rates, can be suggested as alternative therapy for perforator treatment (GRADE 2C).

Pelvic varicosity and pelvic congestion syndrome

Valvular incompetence and retrograde flow to the ovarian veins and/or the internal iliac vein and its tributaries may give rise to pelvic congestion syndrome and pelvic varicosities, which may occur alone or together. Pelvic congestion syndrome is associated with symptoms of pelvic pain or heaviness, dyspareunia, and dysuria. Varicose veins in the vulvar and perivulvar area are most often secondary to previous pregnancy and are often associated with perimenstrual symptoms.

Evaluation. The appearance of varices in the region of the pubis, labia, perineum, or buttocks suggests a pelvic source of reflux. Several noninvasive diagnostic tests are available, including lower extremity, transabdominal, and transvaginal ultrasonography as well as CT and MR venography.³⁷² All have been reported to be useful in documenting pelvic venous reflux, although the selection of the most appropriate test largely depends on local institutional expertise. An ovarian vein diameter of > 6 mm on ultrasonography has been reported to have a 96% positive-predictive

Guideline 14. Treatment of pelvic varicose veins

Guideline No.	14. Treatment of pelvic varicose veins	GRADE of recommendation	Level of evidence
		1. Strong	A. High quality
		2. Weak	B. Moderate quality C. Low or very low quality
14.1	We recommend noninvasive imaging with transabdominal and/or transvaginal ultrasonography, computed tomography or magnetic resonance venography in selected patients with symptoms of pelvic congestion syndrome or symptomatic varices in the distribution of the pubis, labia, perineum, or buttocks.	1	C
14.2	We recommend retrograde ovarian and internal iliac venography in patients with pelvic venous disease, confirmed or suspected by noninvasive imaging studies, in whom intervention is planned.	1	C
14.3	We suggest treatment of pelvic congestion syndrome and pelvic varices with coil embolization, plugs, or transcatheter sclerotherapy, used alone or together.	2	B
14.4	If less invasive treatment is not available or has failed, we suggest surgical ligation and excision of ovarian veins to treat reflux.	2	B

value for pelvic varices.³⁷³ MR and CT venography criteria for pelvic venous varices include four or more tortuous parauterine veins, parauterine veins >4 mm in diameter, and an ovarian vein diameter >8 mm.³⁷⁴

Retrograde ovarian and internal iliac venography is the test of choice for the diagnosis of pelvic venous disorders, although it is most often reserved for patients in whom intervention is planned. Venographic criteria for pelvic congestion syndrome include one or more of the following: (1) an ovarian vein diameter of ≥6 mm, (2) contrast retention for ≥20 seconds, (3) congestion of the pelvic venous plexus and/or opacification of the ipsilateral (or contralateral) internal iliac vein, or (4) filling of vulvovaginal and thigh varicosities.³⁷⁵

Treatment. Various nonsurgical and surgical approaches are available to treat pelvic congestion syndrome. Pharmacologic agents to suppress ovarian function, such as medroxyprogesterone or gonadotropin-releasing hormone, may offer short-term pain relief, but their long-term effectiveness has not been proven. Surgical approaches, including hysterectomy with unilateral or bilateral oophorectomy and ovarian vein ligation and excision, with interruption of as many collateral veins as possible, have been suggested for patients unresponsive to medical therapy.³⁷³

Percutaneous transcatheter embolization of refluxing ovarian and internal iliac vein tributaries with coils, plugs, or sclerotherapy, usually as combination treatment, has become the standard approach for management of both pelvic congestion syndrome and varices arising from a pelvic source.

Results. Transcatheter therapy has been reported to improve symptoms in 50% to 80% of patients. Chung and Huh³⁷⁴ randomized 106 premenopausal women with chronic pelvic pain unresponsive to medical treatment to one of three treatment regimens: (1) ovarian vein embolization, (2) laparoscopic hysterectomy, bilateral salpingo-

oophorectomy, and hormone replacement, or (3) laparoscopic hysterectomy and unilateral oophorectomy. Mean pain scores as assessed on a 10-point visual analog scale were significantly improved among those undergoing ovarian vein embolization or bilateral oophorectomy, but not among those undergoing unilateral oophorectomy. Pain reduction at 12 months was greatest in those undergoing embolotherapy.

CONCLUSIONS

The revolution in endovascular technology has transformed the evaluation and treatment of venous disease during the past decade. To keep up with the rapidly changing technology, in this document the Venous Guideline Committee of the SVS and the AVF provides evidence-based guidelines for the management of varicose veins and associated CVDs in 2011. These guidelines are essential to the clinical practice using evidence-based medicine and play a major role—but not the only role—in determining the best care for patients with varicose veins and more advanced forms of CVD. The scientific evidence presented in this document must be combined with the physician’s clinical experience and the patient’s preference to select the best diagnostic tests and the best treatment option for each individual patient.

AUTHOR CONTRIBUTIONS

Conception and design: PG, AC, MD, BE, DG, MG, JL, RM, MM, HM, FP, PP, MP, JR, MV, TW
 Analysis and interpretation: PG, AC, MD, BE, DG, MG, JL, RM, MM, HM, FP, PP, MP, JR, MV, TW
 Data collection: PG, AC, MD, BE, MG, MM, HM, MP, MV, TW
 Writing the article: PG, MD, BE, MG, RM, FP, PP, MP, JR, MV, TW

Critical revision of the article: PG, AC, MD, BE, DG, MG, JL, RM, MM, HM, FP, PP, MP, JR, MV, TW
 Final approval of the article: PG, AC, MD, BE, DG, MG, JL, RM, MM, HM, FP, PP, MP, JR, MV, TW
 Statistical analysis: Not applicable
 Obtained funding: Not applicable
 Overall responsibility: PG

REFERENCES

- Kaplan RM, Criqui MH, Denenberg JO, Bergan J, Fronck A. Quality of life in patients with chronic venous disease: San Diego population study. *J Vasc Surg* 2003;37:1047-53.
- Smith JJ, Guest MG, Greenhalgh RM, Davies AH. Measuring the quality of life in patients with venous ulcers. *J Vasc Surg* 2000;31:642-9.
- Smith JJ, Garratt AM, Guest M, Greenhalgh RM, Davies AH. Evaluating and improving health-related quality of life in patients with varicose veins. *J Vasc Surg* 1999;30:710-9.
- Korn P, Patel ST, Heller JA, Deitch JS, Krishnasastri KV, Bush HL, et al. Why insurers should reimburse for compression stockings in patients with chronic venous stasis. *J Vasc Surg* 2002;35:950-7.
- Coleridge-Smith P, Labropoulos N, Partsch H, Myers K, Nicolaides A, Cavezzi A, et al. Duplex ultrasound investigation of the veins in chronic venous disease of the lower limbs: UIP consensus document: part I. Basic principles. *Eur J Vasc Endovasc Surg* 2006;31:83-92.
- Hoggan BL, Cameron AL, Maddern GJ. Systematic review of endovenous laser therapy versus surgery for the treatment of saphenous varicose veins. *Ann Vasc Surg* 2009;23:277-87.
- Mundy L, Merlin TL, Fitridge RA, Hiller JE. Systematic review of endovenous laser treatment for varicose veins. *Br J Surg* 2005;92:1189-94.
- Luebke T, Gawenda M, Heckenkamp J, Brunkwall J. Meta-analysis of endovenous radiofrequency obliteration of the great saphenous vein in primary varicosis. *J Endovasc Ther* 2008;15:213-23.
- Luebke T, Brunkwall J. Systematic review and meta-analysis of endovenous radiofrequency obliteration, endovenous laser therapy, and foam sclerotherapy for primary varicosis. *J Cardiovasc Surg* 2008;49:213-33.
- Jia X, Mowatt G, Burr JM, Cassar K, Cook J, Fraser C. Systematic review of foam sclerotherapy for varicose veins. *Br J Surg* 2007;94:925-36.
- Leopardi D, Hoggan BL, Fitridge RA, Woodruff PW, Maddern GJ. Systematic review of treatments for varicose veins. *Ann Vasc Surg* 2009;23:264-76.
- Murad MH, Coto-Yglesias F, Zumaeta-Garcia M, Elamin MB, Dugirala MK, Erwin PJ, et al. A systematic review and meta-analysis of the treatments of varicose veins. *J Vasc Surg* 2011;53(Suppl 2):51S-67S.
- Meissner MH, Gloviczki P, Bergan J, Kistner RL, Morrison N, Pannier F, et al. Primary chronic venous disorders. *J Vasc Surg* 2007;46 (Suppl S):54S-67S.
- Sackett DL. Evidence-based medicine. *Spine (Phila, Pa 1976)*; 1998; 23:1085-6.
- Ruckley CV, Makhdoomi KR. The venous perforator. *Br J Surg* 1996;83:1492-3.
- Porter JM, Moneta GL, International Consensus Committee on Chronic Venous Disease. Reporting standards in venous disease: an update. *J Vasc Surg* 1995;21:635-45.
- Gloviczki P. Do we need evidence-based medicine in the field of venous diseases? *Perspect Vasc Surg Endovasc Ther* 2004;16:129-33.
- O'Donnell TF, Jr, Lau J. A systematic review of randomized controlled trials of wound dressings for chronic venous ulcer. *J Vasc Surg* 2006;44:1118-25.
- O'Donnell TF Jr. The present status of surgery of the superficial venous system in the management of venous ulcer and the evidence for the role of perforator interruption. *J Vasc Surg* 2008;48:1044-52.
- Meissner MH. "I enjoyed your talk, but. . .": evidence-based medicine and the scientific foundation of the American Venous Forum. *J Vasc Surg* 2009;49:244-8.
- Partsch H, Flour M, Smith PC, . Indications for compression therapy in venous and lymphatic disease consensus based on experimental data and scientific evidence: under the auspices of the IUP. *Int Angiol* 2008;27:193-219.
- Nicolaides AN, Allegra C, Bergan J, Bradbury A, Cairons M, Carpenter P, et al. Management of chronic venous disorders of the lower limbs: guidelines according to scientific evidence. *Int Angiol* 2008;27:1-59.
- Hirsh J, Guyatt G, Albers GW, Harrington R, Schunemann HJ, American College of Chest Physicians. Antithrombotic and thrombolytic therapy: American College of Chest Physicians Evidence-Based Clinical Practice Guidelines (8th edition). *Chest*;2008;133(6 suppl):110S-2S.
- Abenham L, Kurz X, VEINES Group. The VEINES study (VENous Insufficiency Epidemiologic and Economic Study): an international cohort study on chronic venous disorders of the leg. *Angiology* 1997;48:59-66.
- Kurz X, Kahn SR, Abenham L, Clement D, Norgren L, Baccaglini U, et al. Chronic venous disorders of the leg: epidemiology, outcomes, diagnosis and management: summary of an evidence-based report of the VEINES Task Force. *Int Angiol* 1999;18:83-102.
- Khilnani NM, Grassi CJ, Kundu S, D'Agostino HR, Khan AA, McGraw JK, et al. Multi-society consensus quality improvement guidelines for the treatment of lower-extremity superficial venous insufficiency with endovenous thermal ablation from the Society of Interventional Radiology, Cardiovascular Interventional Radiological Society of Europe, American College of Phlebology and Canadian Interventional Radiology Association. *J Vasc Interv Radiol* 2010; 21:14-31.
- American Academy of Dermatology. Guidelines of care for sclerotherapy treatment of varicose and telangiectatic leg veins. *J Am Acad Dermatol* 1996;34:523-8.
- The Alexander House Group. Consensus paper on venous leg ulcer. *J Dermatol Surg Oncol* 1992;18:592-602.
- Rabe E, Pannier-Fischer F, Gerlach H, Breu FX, Guggenbichler S, Zabel M, et al. Guidelines for sclerotherapy of varicose veins (ICD 10: I83.0, I83.1, I83.2, and I83.9). *Dermatol Surg* 2004;30:687-93.
- Robson MC, Cooper DM, Aslam R, Gould LJ, Harding KG, Margolis DJ, et al. Guidelines for the treatment of venous ulcers. *Wound Repair Regen* 2006;14:649-62.
- Agus GB, Allegra C, Antignani PL, Arpaia G, Bianchini G, Bonadeo P, et al. Guidelines for the diagnosis and therapy of the vein and lymphatic disorders. *Int Angiol* 2005;24:107-68.
- Luebke T, Brunkwall J. Meta-analysis of subfascial endoscopic perforator vein surgery (SEPS) for chronic venous insufficiency. *Phlebology* 2009;24:8-16.
- Luebke T, Brunkwall J. Meta-analysis of transilluminated powered phlebectomy for superficial varicosities. *J Cardiovasc Surg* 2008;49:757-64.
- Palfreyman SJ, Michaels JA. A systematic review of compression hosiery for uncomplicated varicose veins. *Phlebology* 2009;24 (suppl 1):13-33.
- Palfreyman SJ, Lochiel R, Michaels JA. A systematic review of compression therapy for venous leg ulcers. *Vasc Med* 1998;3:301-13.
- Fletcher A, Cullum N, Sheldon TA. A systematic review of compression treatment for venous leg ulcers. *BMJ* 1997;315:576-80.
- Scurr JR, Gilling-Smith GL, Fisher RK. Systematic review of foam sclerotherapy for varicose veins (Br J Surg 2007; 94: 925-936). *Br J Surg* 2007;94:1307-8.
- Tenbrook JA Jr, Iafrafi MD, O'Donnell TF Jr, Wolf MP, Hoffman SN, Pauker SG, et al. Systematic review of outcomes after surgical management of venous disease incorporating subfascial endoscopic perforator surgery. *J Vasc Surg* 2004;39:583-9.
- Bamigboye AA, Smyth R. Interventions for varicose veins and leg oedema in pregnancy. *Cochrane Database Syst Rev* 2007:CD001066.
- Tisi PV, Beverley C, Rees A. Injection sclerotherapy for varicose veins. *Cochrane Database Syst Rev* 2006:CD001732.
- O'Meara S, Cullum NA, Nelson EA. Compression for venous leg ulcers. *Cochrane Database Syst Rev* 2009:CD000265.

42. Palfreyman SJ, Nelson EA, Lochiel R, Michaels JA. Dressings for healing venous leg ulcers. *Cochrane Database Syst Rev* 2006; CD001103.
43. Meissner MH, Eklof B, Smith PC, Dalsing MC, DePalma RG, Gloviczki P, et al. Secondary chronic venous disorders. *J Vasc Surg* 2007;46 (suppl S):68-83S.
44. Meissner MH, Moneta G, Burnand K, Gloviczki P, Lohr JM, Lurie F, et al. The hemodynamics and diagnosis of venous disease. *J Vasc Surg* 2007;46 (suppl S):4-24S.
45. Henke P; Writing Group I of the Pacific Vascular Symposium 6, Vandy F, Comerota A, Kahn SR, Lal BK, et al. Prevention and treatment of the postthrombotic syndrome. *J Vasc Surg* 2010;52(5 Suppl):21S-28S.
46. Henke P, Kistner B, Wakefield TW, Eklof B, Lurie F. Reducing venous stasis ulcers by fifty percent in 10 years: the next steps. *J Vasc Surg* 2010;52(5 suppl):37S-8S.
47. Gloviczki P, editor. *Handbook of venous disorders: guidelines of the American Venous Forum*. 3rd ed. London: Hodder Arnold; 2009.
48. Guyatt G, Gutterman D, Baumann MH, Addrizzo-Harris D, Hylek EM, Phillips B, et al. Grading strength of recommendations and quality of evidence in clinical guidelines: report from an American College of Chest Physicians task force. *Chest* 2006;129:174-81.
49. Caggiati A, Bergan JJ, Gloviczki P, Eklof B, Allegra C, Partsch H, et al. Nomenclature of the veins of the lower limb: extensions, refinements, and clinical application. *J Vasc Surg* 2005;41:719-24.
50. Mozes G, Gloviczki P. New discoveries in anatomy and new terminology of leg veins: clinical implications. *Vasc Endovasc Surg* 2004;38:367-74.
51. Eklof B, Perrin M, Delis KT, Rutherford RB, Gloviczki P, et al. Updated terminology of chronic venous disorders: the VEIN-TERM transatlantic interdisciplinary consensus document. *J Vasc Surg* 2009;49:498-501.
52. Caggiati A, Bergan JJ, Gloviczki P, Jantet G, Wendell-Smith CP, Partsch H, et al. Nomenclature of the veins of the lower limbs: an international interdisciplinary consensus statement. *J Vasc Surg* 2002;36:416-22.
53. Kistner RL, Eklof B. Classification and etiology of chronic venous disease. In: Gloviczki P, editor. *Handbook of venous disorders: guidelines of the American Venous Forum*. 3rd ed. London: Hodder Arnold; 2009, p. 37-46.
54. Labropoulos N, Giannoukas AD, Delis K, Mansour MA, Kang SS, Nicolaides AN, et al. Where does venous reflux start? *J Vasc Surg* 1997;26:736-42.
55. Raju S, Neglén P. Clinical practice. Chronic venous insufficiency and varicose veins. *N Engl J Med* 2009;360:2319-27.
56. Eberhardt RT, Raffetto JD. Chronic venous insufficiency. *Circulation* 2005;111:2398-409.
57. Rabe E, Pannier F. Epidemiology of chronic venous disorders. In: Gloviczki P, editor. *Handbook of venous disorders: guidelines of the American Venous Forum*. 3rd ed. London: Hodder Arnold; 2009, p. 105-10.
58. Heit JA, Silverstein MD, Mohr DN, Petterson TM, Lohse CM, O'Fallon WM, et al. The epidemiology of venous thromboembolism in the community. *Thromb Hemost* 2001;86:452-63.
59. Rabe E, Pannier-Fischer F, Bromen K, Schuldt K, Stang A, Poncar C, et al. Bonner Venenstudie der Deutschen Gesellschaft für Phlebologie Epidemiologische Untersuchung zur Frage der Häufigkeit und Ausprägung von chronischen Venenkrankheiten in der städtischen und ländlichen Wohnbevölkerung. *Phlebologie* 2003;32:1-14.
60. Carpentier PH, Maricq HR, Biro C, Ponçot-Makinen CO, Franco A. Prevalence, risk factors, and clinical patterns of chronic venous disorders of lower limbs: a population-based study in France. *J Vasc Surg* 2004;40:650-9.
61. McLafferty RB, Passman MA, Caprini JA, Rooke TW, Markwell SA, Lohr JM, et al. Increasing awareness about venous disease: the American Venous Forum expands the national venous screening program. *J Vasc Surg* 2008;48:394-9.
62. Gloviczki P, Bergan JJ, Menawat SS, Hobson RW 2nd, Kistner RL, Lawrence PF, et al. Safety, feasibility, and early efficacy of subfascial endoscopic perforator surgery: a preliminary report from the North American registry. *J Vasc Surg* 1997;25:94-105.
63. Bauer G. The etiology of leg ulcers and their treatment with resection of the popliteal vein. *J Int Chir* 1948;8:937-61.
64. Henke P. The Pacific Vascular Symposium 6: the Venous Ulcer Summit in perspective. *J Vasc Surg* 2010;52(5 suppl):1S-2S.
65. Delis KT, Knaggs AL, Khodabakhsh P. Prevalence, anatomic patterns, valvular competence, and clinical significance of the Giacomini vein. *J Vasc Surg* 2004;40:1174-83.
66. Mozes G, Gloviczki P, Menawat SS, Fisher DR, Carmichael SW, Kadar A, et al. Surgical anatomy for endoscopic subfascial division of perforating veins. *J Vasc Surg* 1996;24:800-8.
67. Pang AS. Location of valves and competence of the great saphenous vein above the knee. *Ann Acad Med Singapore* 1991;20:248-50.
68. Gloviczki P, Mozes G. Development and anatomy of the venous system. In: Gloviczki P, editor. *Handbook of venous disorders: guidelines of the American Venous Forum*. 3rd ed. London: Hodder Arnold; 2009, p. 12-24.
69. LePage PA, Villavicencio JL, Gomez ER, Sheridan MN, Rich NM. The valvular anatomy of the iliac venous system and its clinical implications. *J Vasc Surg* 1991;14:678-83.
70. Langer RD, Ho E, Denenberg JO, Fronck A, Allison M, Criqui MH, et al. Relationships between symptoms and venous disease: the San Diego population study. *Arch Intern Med* 2005;165:1420-4.
71. Bradbury A, Ruckley CV. Clinical presentation and assessment of patients with venous disease. In: Gloviczki P, editor. *Handbook of venous disorders: guidelines of the American Venous Forum*. 3rd ed. London: Hodder Arnold; 2009, p. 331-41.
72. Jiang P, van Rij AM, Christie R, Hill G, Solomon C, Thomson I. Recurrent varicose veins: patterns of reflux and clinical severity. *Cardiovas Surg* 1999;7:332-9.
73. Jiang P, van Rij AM, Christie RA, Hill GB, Thomson IA. Non-saphenofemoral venous reflux in the groin in patients with varicose veins. *Eur J Vasc Endovasc Surg* 2001;21:550-7.
74. Gloviczki P, Driscoll DJ. Klippel-Trenaunay syndrome: current management. *Phlebology* 2007;22:291-8.
75. Gloviczki P, Duncan A, Kalra M, Oderich G, Ricotta J, Bower T, et al. Vascular malformations: an update. *Perspect Vasc Surg Endovasc Ther* 2009;21:133-48.
76. Nicolaides A, Bergan JJ, Eklof B, Kistner RL, Moneta G, Ad Hoc Committee of the American Venous Forum. Classification and grading of chronic venous disease in the lower limbs: a consensus statement. In: Gloviczki P, Yao JST editors. *Handbook of venous disorders: guidelines of the American Venous Forum*. London: Chapman & Hall Medical; 1996, p. 652-60.
77. Eklof B, Rutherford RB, Bergan JJ, Carpentier PH, Gloviczki P, Kistner RL, et al. Revision of the CEAP classification for chronic venous disorders: consensus statement. *J Vasc Surg* 2004;40:1248-52.
78. Vasquez MA, Rabe E, McLafferty RB, Shortell CK, Marston WA, Gillespie D, et al. Revision of the venous clinical severity score: venous outcomes consensus statement: Special communication of the American Venous Forum Ad Hoc Outcomes Working Group. *J Vasc Surg* 2010;52:1387-96.
79. Cavezzi A, Labropoulos N, Partsch H, Ricci S, Caggiati A, Myers K, et al. Duplex ultrasound investigation of the veins in chronic venous disease of the lower limbs—UIP consensus document. Part II. Anatomy. *Eur J Vasc Endovasc Surg* 2006;31:288-99.
80. McMullin GM, Smith C. An evaluation of Doppler ultrasound and photoplethysmography in the investigation of venous insufficiency. *Aust N Z J Surg* 1992;62:270-5.
81. Labropoulos N, Tiongson J, Pryor L, Tassiopoulos AK, Kang SS, Ashraf Mansour M, et al. Definition of venous reflux in lower-extremity veins. *J Vasc Surg* 2003;38:793-8.
82. Labropoulos N. Vascular diagnosis of venous thrombosis. In: Mansour MA, Labropoulos N, editors. *Vascular diagnosis*. Philadelphia: Elsevier Saunders; 2005, p. 429-38.
83. Blebea J, Kihara TK, Neumyer MM, Blebea JS, Anderson KM, Atnip RG, et al. A national survey of practice patterns in the noninvasive diagnosis of deep venous thrombosis. *J Vasc Surg* 1999;29:799-804.

84. Markel A, Meissner MH, Manzo RA, Bergelin RO, Strandness DE. A comparison of the cuff deflation method with Valsalva's maneuver and limb compression in detecting venous valvular reflux. *Arch Surg* 1994;129:701-5.
85. van Bemmelen PS, Bedford G, Beach K, Strandness DE. Quantitative segmental evaluation of venous valvular reflux with duplex ultrasound scanning. *J Vasc Surg* 1989;10:425-31.
86. Nicolaides AN; Cardiovascular Disease Educational and Research Trust, European Society of Vascular Surgery, the International Angiology Scientific Activity Congress Organization, International Union of Angiology, Union Internationale de Phlebologie at the Abbaye des Vaux de Cernay. Investigation of chronic venous insufficiency: a consensus statement (France, March 5-9, 1997). *Circulation* 2000;129:E126-63.
87. Labropoulos N, Mansour MA, Kang SS, Gloviczki P, Baker WH. New insights into perforator vein incompetence. *Eur J Vasc Endovasc Surg* 1999;18:228-34.
88. Abai B, Labropoulos N. Duplex ultrasound scanning for chronic venous obstruction and valvular incompetence. In: Gloviczki P, editor. *Handbook of venous disorders: guidelines of the American Venous Forum*. 3rd ed. London: Hodder Arnold; 2009, p. 142-55.
89. Sandri JL, Barros FS, Pontes S, Jacques C, Salles-Cunha SX. Diameter-reflux relationship in perforating veins of patients with varicose veins. *J Vasc Surg* 1999;30:867-74.
90. Kistner RL, Eklof B, Masuda EM. Diagnosis of chronic venous disease of the lower extremities: the "CEAP" classification. *Mayo Clin Proc* 1996;71:338-45.
91. Hanrahan LM, Araki CT, Rodriguez AA, Kechejian GJ, LaMorte WW, Menzoian JO, et al. Distribution of valvular incompetence in patients with venous stasis ulceration. *J Vasc Surg* 1991;13:805-11.
92. Labropoulos N, Leon M, Geroulakos G, Volteas N, Chan P, Nicolaides AN. Venous hemodynamic abnormalities in patients with leg ulceration. *Am J Surg* 1995;169:572-4.
93. Labropoulos N, Giannoukas AD, Nicolaides AN, Veller M, Leon M, Volteas N, et al. The role of venous reflux and calf muscle pump function in nonthrombotic chronic venous insufficiency. Correlation with severity of signs and symptoms. *Arch Surg* 1996;131:403-6.
94. Struckmann JR. Assessment of the venous muscle pump function by ambulatory strain gauge plethysmography. Methodological and clinical aspects. *Dan Med Bull* 1993;40:460-77.
95. Rhodes JM, Gloviczki P, Canton L, Heaser TV, Rooke TW. Endoscopic perforator vein division with ablation of superficial reflux improves venous hemodynamics. *J Vasc Surg* 1998;28:839-47.
96. Rooke TW, Hesser JL, Osmundson PJ. Exercise strain-gauge venous plethysmography: evaluation of a "new" device for assessing lower limb venous incompetence. *Angiology* 1992;43:219-28.
97. Struckmann J. Venous investigations: the current position. *Angiology* 1994;45:505-11.
98. Criado E, Farber MA, Marston WA, Daniel PF, Burnham CB, Keagy BA, et al. The role of air plethysmography in the diagnosis of chronic venous insufficiency. *J Vasc Surg* 1998;27:660-70.
99. Park UJ, Yun WS, Lee KB, Rho YN, Kim YW, Joh JH, et al. Analysis of the postoperative hemodynamic changes in varicose vein surgery using air plethysmography. *J Vasc Surg* 2010;51:634-8.
100. Lurie F, Rooke TW. Evaluation of venous function by indirect non-invasive testing (plethysmography). In: Gloviczki P, editor. *Handbook of venous disorders: guidelines of the American Venous Forum*. 3rd ed. London: Hodder Arnold; 2009, p. 156-9.
101. Neglen P, Raju S. Intravascular ultrasound scan evaluation of the obstructed vein. *J Vasc Surg* 2002;35:694-700.
102. Reed NR, Kalra M, Bower TC, Vrtiska TJ, Ricotta JJ 2nd, Gloviczki P, et al. Left renal vein transposition for nutcracker syndrome. *J Vasc Surg* 2009;49:386-93.
103. Labropoulos N, Manalo D, Patel NP, Tiongson J, Pryor L, Giannoukas AD, et al. Uncommon leg ulcers in the lower extremity. *J Vasc Surg* 2007;45:568-73.
104. Rutherford RB, Moneta GL, Padberg FT Jr, Meissner MH. Outcome assessment in chronic venous disease. In: Gloviczki P, editor. *Handbook of venous disorders: guidelines of the American Venous Forum*. 3rd ed. London: Hodder Arnold; 2009, p. 684-93.
105. Baker DM, Turnbull NB, Pearson JC, Makin GS. How successful is varicose vein surgery? A patient outcome study following varicose vein surgery using the SF-36 Health Assessment Questionnaire. *Eur J Vasc Endovasc Surg* 1995;9:299-304.
106. Pannier F, Hoffmann B, Stang A, Jockel K-H, Rabe E. Prevalence and acceptance of therapy with medical compression stockings: results of the Bonn Vein Study. *Phlebologie* 2007;36:245-9.
107. Davies AH, Rudarakanchana N. Quality of life and outcome assessment in patients with varicose veins. In: Davies AH, Lees TA, Lane IF, editors. *Venous disease simplified*. Shropshire, UK: TFM Publishing Ltd; 2006.
108. Vasquez MA, Munschauer CE. Venous Clinical Severity Score and quality-of-life assessment tools: application to vein practice. *Phlebology* 2008;23:259-75.
109. Lamping DL, Schroter S, Kurz X, Kahn SR, Abenham L. Evaluation of outcomes in chronic venous disorders of the leg: development of a scientifically rigorous, patient-reported measure of symptoms and quality of life. *J Vasc Surg* 2003;37:410-9.
110. Franks PJ, Moffatt CJ. Health related quality of life in patients with venous ulceration: use of the Nottingham health profile. *Qual Life Res* 2001;10:693-700.
111. Wiebe S, Guyatt G, Weaver B, Matijevic S, Sidwell C. Comparative responsiveness of generic and specific quality-of-life instruments. *J Clin Epidemiol* 2003;56:52-60.
112. Kahn SR, M'Lan CE, Lamping DL, Kurz X, Berard A, Abenham LA, et al. Relationship between clinical classification of chronic venous disease and patient-reported quality of life: results from an international cohort study. *J Vasc Surg* 2004;39:823-8.
113. Launois R, Mansilha A, Jantet G. International psychometric validation of the Chronic Venous Disease quality of life Questionnaire (CIVIQ-20). *Eur J Vasc Endovasc Surg* 2010;40:783-9.
114. Garratt AM, Macdonald LM, Ruta DA, Russell IT, Buckingham JK, Krukowski ZH, et al. Towards measurement of outcome for patients with varicose veins. *Qual Health Care* 1993;2:5-10.
115. Garratt AM, Ruta DA, Abdalla MI, Russell IT. SF 36 health survey questionnaire: II. Responsiveness to changes in health status in four common clinical conditions. *Qual Health Care* 1994;3:186-92.
116. Ricci MA, Emmerich J, Callas PW, Rosendaal FR, Stanley AC, Naud S, et al. Evaluating chronic venous disease with a new venous severity scoring system. *J Vasc Surg* 2003;38:909-15.
117. Rutherford RB, Padberg FT, Jr, Comerota AJ, Kistner RL, Meissner MH, Moneta GL, et al. Venous severity scoring: an adjunct to venous outcome assessment. *J Vasc Surg* 2000;31:1307-12.
118. Meissner MH, Natiello C, Nicholls SC. Performance characteristics of the venous clinical severity score. *J Vasc Surg* 2002;36:889-95.
119. Mekako AI, Hatfield J, Bryce J, Lee D, McCollum PT, Chetter I. A nonrandomised controlled trial of endovenous laser therapy and surgery in the treatment of varicose veins. *Ann Vasc Surg* 2006;20:451-7.
120. Gillet JL, Perrin MR, Allaert FA. Clinical presentation and venous severity scoring of patients with extended deep axial venous reflux. *J Vasc Surg* 2006;44:588-94.
121. Kakkos SK, Rivera MA, Matsagas MI, Lazarides MK, Robless P, Belcaro G, et al. Validation of the new venous severity scoring system in varicose vein surgery. *J Vasc Surg* 2003;38:224-8.
122. Vasquez MA, Wang J, Mahathanaruk M, Buczkowski G, Sprehe E, Dosluoglu HH, et al. The utility of the Venous Clinical Severity Score in 682 limbs treated by radiofrequency saphenous vein ablation. *J Vasc Surg* 2007;45:1008-14.
123. Vasquez MA, Rabe E, McLafferty RB, Shortell CK, Marston WA, Gillespie D, et al. Revision of the venous clinical severity score: venous outcomes consensus statement: special communication of the American Venous Forum Ad Hoc Outcomes Working Group. *J Vasc Surg* 2010;52:1387-96.
124. Kundu S, Lurie F, Millward SF, Padberg F Jr, Vedantham S, Elias S, et al. Recommended reporting standards for endovenous ablation for the treatment of venous insufficiency: joint statement of the American Venous Forum and the Society of Interventional Radiology. *J Vasc Surg* 2007;46:582-9.

125. Perrin M, Allaert FA. Intra- and inter-observer reproducibility of the Recurrent Varicose Veins after Surgery (REVAS) classification. *Eur J Vasc Endovasc Surg* 2006;32:326-32.
126. Pittaluga P, Chastanet S, Rea B, Barbe R. Midterm results of the surgical treatment of varices by phlebectomy with conservation of a refluxing saphenous vein. *J Vasc Surg* 2009;50:107-18.
127. Padberg FT Jr, Pappas PJ, Araki CT, Back TL, Hobson RW 2nd. Hemodynamic and clinical improvement after superficial vein ablation in primary combined venous insufficiency with ulceration. *J Vasc Surg* 1996;24:711-8.
128. Ramelet AA, Boisseau MR, Allegra C, Nicolaides A, Jaeger K, Carpentier P, et al. Veno-active drugs in the management of chronic venous disease. An international consensus statement: current medical position, prospective views and final resolution. *Clin Hemorheol Microcirc* 2005;33:309-19.
129. Pittler MH, Ernst E. Horse chestnut seed extract for chronic venous insufficiency. *Cochrane Database Syst Rev* 2006:CD003230.
130. Coleridge-Smith P, Lok C, Ramelet AA. Venous leg ulcer: a meta-analysis of adjunctive therapy with micronized purified flavonoid fraction. *Eur J Vasc Endovasc Surg* 2005;30:198-208.
131. Coleridge-Smith PD. Drug treatment of varicose veins, venous edema, and ulcers. In: Gliviczki P, editor. *Handbook of venous disorders: guidelines of the American Venous Forum*. 3rd ed. London: Hodder Arnold; 2009, p. 359-65.
132. Martinez MJ, Bonfill X, Moreno RM, Vargas E, Capella D. Phlebtonics for venous insufficiency. *Cochrane Database Syst Rev* 2005: CD003229.
133. Dale JJ, Ruckley CV, Harper DR, Gibson B, Nelson EA, Prescott RJ. Randomised, double blind placebo controlled trial of pentoxifylline in the treatment of venous leg ulcers. *BMJ* 1999;319:875-8.
134. Falanga V, Fujitani RM, Diaz C, Hunter G, Jorizzo J, Lawrence PF, et al. Systemic treatment of venous leg ulcers with high doses of pentoxifylline: efficacy in a randomized, placebo-controlled trial. *Wound Repair Regen* 1999;7:208-13.
135. Nelson EA, Prescott RJ, Harper DR, Gibson B, Brown D, Ruckley CV, et al. A factorial, randomized trial of pentoxifylline or placebo, four-layer or single-layer compression, and knitted viscose or hydrocolloid dressings for venous ulcers. *J Vasc Surg* 2007;45:134-41.
136. Hirsh J, Guyatt G, Albers GW, Harrington R, Schunemann HJ. Executive summary: American College of Chest Physicians Evidence-Based Clinical Practice Guidelines (8th Edition). *Chest* 2006;133(6 suppl):71-109S.
137. Guilhou JJ, Dereure O, Marzin L, Ouvry P, Zuccarelli F, Debure C, et al. Efficacy of Daflon 500 mg in venous leg ulcer healing: a double-blind, randomized, controlled versus placebo trial in 107 patients. *Angiology* 1997;48:77-85.
138. Moneta GL, Partsch H. Compression therapy for venous ulceration. In: Gliviczki P, editor. *Handbook of venous disorders: guidelines of the American Venous Forum*. 3rd ed. London: Hodder Arnold; 2009, p. 348-58.
139. Partsch B, Partsch H. Calf compression pressure required to achieve venous closure from supine to standing positions. *J Vasc Surg* 2005; 42:734-8.
140. Motykie GD, Caprini JA, Arcelus JI, Reyna JJ, Overom E, Mokhtee D, et al. Evaluation of therapeutic compression stockings in the treatment of chronic venous insufficiency. *Dermatol Surg* 1999;25:116-20.
141. Amsler F, Blattler W. Compression therapy for occupational leg symptoms and chronic venous disorders: a meta-analysis of randomised controlled trials. *Eur J Vasc Endovasc Surg* 2008;35:366-72.
142. Callam MJ, Ruckley CV, Dale JJ, Harper DR. Hazards of compression treatment of the leg: an estimate from Scottish surgeons. *Br Med J (Clin Res Ed)* 1987;295:1382.
143. Michaels JA, Brazier JE, Campbell WB, MacIntyre JB, Palfreyman SJ, Ratcliffe J. Randomized clinical trial comparing surgery with conservative treatment for uncomplicated varicose veins. *Br J Surg* 2006;93: 175-81.
144. Michaels JA, Campbell WB, Brazier JE, Macintyre JB, Palfreyman SJ, Ratcliffe J, et al. Randomised clinical trial, observational study and assessment of cost-effectiveness of the treatment of varicose veins (REACTIV trial). *Health Technol Assess* 2006;10:1-196.
145. Franks PJ, Moffatt CJ, Connolly M, Bosanquet N, Oldroyd MI, Greenhalgh RM, et al. Factors associated with healing leg ulceration with high compression. *Age Ageing* 1995;24:407-10.
146. Ibegbuna V, Delis KT, Nicolaides AN, Aina O. Effect of elastic compression stockings on venous hemodynamics during walking. *J Vasc Surg* 2003;37:420-5.
147. Zajkowski PJ, Proctor MC, Wakefield TW, Bloom J, Blessing B, Greenfield LJ, et al. Compression stockings and venous function. *Arch Surg* 2002;137:1064-8.
148. Mayberry JC, Moneta GL, Taylor LM, Jr, Porter JM. Fifteen-year results of ambulatory compression therapy for chronic venous ulcers. *Surgery* 1991;109:575-81.
149. Kikta MJ, Schuler JJ, Meyer JP, Durham JR, Eldrup-Jorgensen J, Schwarcz TH, et al. A prospective, randomized trial of Unna's boots versus hydroactive dressing in the treatment of venous stasis ulcers. *J Vasc Surg* 1988;7:478-83.
150. Callam MJ, Harper DR, Dale JJ, et al. Lothian and Forth Valley leg ulcer healing trial: part 1. Elastic versus non-elastic bandaging in the treatment of chronic leg ulceration. *Phlebology* 1992;7:136-41.
151. Partsch H, Menzinger G, Mostbeck A. Inelastic leg compression is more effective to reduce deep venous refluxes than elastic bandages. *Dermatol Surg* 1999;25:695-700.
152. Amsler F, Willenberg T, Blättler W. In search of optimal compression therapy for venous leg ulcers: a meta-analysis of studies comparing diverse [corrected] bandages with specifically designed stockings. *J Vasc Surg* 2009;50:668-74.
153. Partsch H, Flour M, Smith PC. Indications for compression therapy in venous and lymphatic disease consensus based on experimental data and scientific evidence. Under the auspices of the IUP. *Int Angiol* 2008;27:193-219.
154. Coleridge-Smith PD. Leg ulcer treatment. *J Vasc Surg* 2009;49: 804-8.
155. Milic DJ, Zivic SS, Bogdanovic DC, Perisic ZD, Milosevic ZD, Jankovic RJ, et al. A randomized trial of the Tubulcus multilayer bandaging system in the treatment of extensive venous ulcers. *J Vasc Surg* 2007;46:750-5.
156. Barwell JR, Davies CE, Deacon J, Harvey K, Minor J, Sassano A, et al. Comparison of surgery and compression with compression alone in chronic venous ulceration (ESCHAR study): randomised controlled trial. *Lancet* 2004;363:1854-9.
157. Gohel MS, Barwell JR, Taylor M, Chant T, Foy C, Earnshaw JJ, et al. Long term results of compression therapy alone versus compression plus surgery in chronic venous ulceration (ESCHAR): randomised controlled trial. *BMJ* 2007;335:83.
158. Gardiner R, Negus D. Compression hosiery: compression measurements and fitting. In: Negus D, Coleridge-Smith PD, Bergan JJ, editors. *Leg ulcers: diagnosis and management*. 3rd ed. London: Hodder Arnold; 2005, p. 227-32.
159. Geerts WH, Bergqvist D, Pineo GF, Heit JA, Samama CM, Lassen MR, et al. Prevention of venous thromboembolism: American College of Chest Physicians Evidence-Based Clinical Practice Guidelines (8th Edition). *Chest* 2008;133(6 suppl):381-453S.
160. Scriven JM, Hartshorne T, Thrush AJ, Bell PR, Naylor AR, London NJ. Role of saphenous vein surgery in the treatment of venous ulceration. *Br J Surg* 1998;85:781-4.
161. Palfreyman S, Nelson EA, Michaels JA. Dressings for venous leg ulcers: systematic review and meta-analysis. *BMJ* 2007;335:244.
162. Keller WL. A new method of extirpating the internal saphenous and similar veins in varicose conditions: a preliminary report. *N Y Med J* 1905;82:385.
163. Mayo CH. Treatment of varicose veins. *Surg Obstet Gynecol* 1906;2: 385-8.
164. Babcock WW. A new operation for the extirpation of varicose veins of the leg. *N Y Med J* 1907;86:153-6.
165. Holme JB, Skajaa K, Holme K. Incidence of lesions of the saphenous nerve after partial or complete stripping of the long saphenous vein. *Acta Chir Scand* 1990;156:145-8.
166. Van Der Stricht J. [Saphenectomy by invagination by thread]. *Presse Med* 1963;71:1081-2.

167. Fullarton GM, Calvert MH. Intraluminal long saphenous vein stripping: a technique minimizing perivenous tissue trauma. *Br J Surg* 1987;74:255.
168. Oesch A. "Pin-stripping": a novel method of atraumatic stripping. *Phlebology* 1993;4:171-3.
169. Goren G, Yellin AE. Invaginated axial saphenectomy by a semirigid stripper: perforate-invaginate stripping. *J Vasc Surg* 1994;20:970-7.
170. Myers TT, Smith LR. Results of the stripping operation in the treatment of varicose veins. *Proc Staff Meet Mayo Clin* 1954;29:583-90.
171. Lofgren EP. Trends in the surgical management of varicose veins. *Mayo Clin Proc* 1980;55:583-4.
172. Goren G, Yellin AE. Minimally invasive surgery for primary varicose veins: limited invaginated axial stripping and tributary (hook) stab avulsion. *Ann Vasc Surg* 1995;9:401-14.
173. Bergan JJ. Varicose veins: hooks, clamps, and suction: application of new techniques to enhance varicose vein surgery. *Semin Vasc Surg* 2002;15:21-6.
174. Scavee V, Lesceu O, Theys S, Jamart J, Louagie Y, Schoevaerdt JC, et al. Hook phlebectomy versus transilluminated powered phlebectomy for varicose vein surgery: early results. *Eur J Vasc Endovasc Surg* 2003;25:473-5.
175. Aremu MA, Mahendran B, Butcher W, Khan Z, Colgan MP, Moore DJ, et al. Prospective randomized controlled trial: conventional versus powered phlebectomy. *J Vasc Surg* 2004;39:88-94.
176. Chetter IC, Mylankal KJ, Hughes H, Fritridge R. Randomized clinical trial comparing multiple stab incision phlebectomy and transilluminated powered phlebectomy for varicose veins. *Br J Surg* 2006;93:169-74.
177. Rasmussen LH, Bjoern L, Lawaetz M, Lawaetz B, Blemings A, Eklof B, et al. Randomised clinical trial comparing endovenous laser ablation with stripping of the great saphenous vein: clinical outcome and recurrence after 2 years. *Eur J Vasc Endovasc Surg* 2010;39:630-5.
178. Perkins JM. Standard varicose vein surgery. *Phlebology* 2009;24 (suppl 1):34-41.
179. Menyhei G, Gyevnar Z, Arato E, Kelemen O, Kollar L. Conventional stripping versus cryostripping: a prospective randomised trial to compare improvement in quality of life and complications. *Eur J Vasc Endovasc Surg* 2008;35:218-23.
180. Garde C. Cryosurgery of varicose veins. *J Dermatol Surg Oncol* 1994;20:56-8.
181. Kabnick LS. Phlebectomy. In: Gloviczki P, editor. *Handbook of venous disorders: guidelines of the American Venous Forum*. 3rd ed. London: Hodder Arnold; 2009, p. 429-38.
182. Lawrence PF, Vardanian AJ. Light-assisted stab phlebectomy: report of a technique for removal of lower extremity varicose veins. *J Vasc Surg* 2007;46:1052-4.
183. Klein JA. Anesthetic formulation of tumescent solutions. *Dermatol Clin* 1999;17:751-9.
184. Passman M. Transilluminated powered phlebectomy in the treatment of varicose veins. *Vascular* 2007;15:262-8.
185. Cheshire N, Elias SM, Keagy B, Kolvenbach R, Leahy AL, Marston W, et al. Powered phlebectomy (trivex) in treatment of varicose veins. *Ann Vasc Surg* 2002;16:488-94.
186. Criado E, Lujan S, Izquierdo L, Puras E, Gutierrez M, Fontcuberta J. Conservative hemodynamic surgery for varicose veins. *Semin Vasc Surg* 2002;15:27-33.
187. Franceschi C. Théorie et pratique de la cure conservatrice et hémodynamique de l'insuffisance veineuse en ambulatoire. *Précis-sous-Thil: Armançon*; 1988.
188. Zamboni P, Cisno C, Marchetti F, Mazza P, Fogato L, Carandina S, et al. Minimally invasive surgical management of primary venous ulcers vs. compression treatment: a randomized clinical trial. *Eur J Vasc Endovasc Surg* 2003;25:313-8.
189. Maeso J, Juan J, Escribano J, Allegue NM, Di Matteo A, Conzaes E, et al. Comparison of clinical outcome of stripping and CHIVA for treatment of varicose veins in the lower extremities. *Ann Vasc Surg* 2001;15:661-5.
190. Mowatt-Larssen E, Shortell C. CHIVA. *Semin Vasc Surg* 2010;23:118-22.
191. Carandina S, Mari C, De Palma M, Marcellino MG, Cisno C, Legnaro A, et al. Varicose vein stripping vs haemodynamic correction (CHIVA): a long term randomised trial. *Eur J Vasc Endovasc Surg* 2008;35:230-7.
192. Parés JO, Juan J, Tellez R, Mata A, Moreno C, Quer FX, et al. Varicose vein surgery: stripping versus the CHIVA method: a randomized controlled trial. *Ann Surg* 2010;251:624-31.
193. MacKenzie RK, Allan PL, Ruckley CV, Bradbury AW. The effect of long saphenous vein stripping on deep venous reflux. *Eur J Vasc Endovasc Surg* 2004;28:104-7.
194. Sam RC, MacKenzie RK, Paisley AM, Ruckley CV, Bradbury AW. The effect of superficial venous surgery on generic health-related quality of life. *Eur J Vasc Endovasc Surg* 2004;28:253-6.
195. Lurie F, Creton D, Eklof B, Kabnick LS, Kistner RL, Pichot O, et al. Prospective randomized study of endovenous radiofrequency obliteration (closure procedure) versus ligation and stripping in a selected patient population (EVOLVE Study). *J Vasc Surg* 2003;38:207-14.
196. Dwerryhouse S, Davies B, Harradine K, Earnshaw JJ. Stripping the long saphenous vein reduces the rate of reoperation for recurrent varicose veins: five-year results of a randomized trial. *J Vasc Surg* 1999;29:589-92.
197. Frings N, Nelle A, Tran P, Fischer R, Krug W. Reduction of neoreflux after correctly performed ligation of the saphenofemoral junction: a randomized trial. *Eur J Vasc Endovasc Surg* 2004;28:246-52.
198. Winterborn RJ, Foy C, Heather BP, Earnshaw JJ. Randomised trial of flush saphenofemoral ligation for primary great saphenous varicose veins. *Eur J Vasc Endovasc Surg* 2008;36:477-84.
199. van Rij AM, Jones GT, Hill BG, Amer M, Thomson IA, Pettigrew RA, et al. Mechanical inhibition of angiogenesis at the saphenofemoral junction in the surgical treatment of varicose veins: early results of a blinded randomized controlled trial. *Circulation* 2008;118:66-74.
200. Winterborn RJ, Earnshaw JJ. Randomised trial of polytetrafluoroethylene patch insertion for recurrent great saphenous varicose veins. *Eur J Vasc Endovasc Surg* 2007;34:367-73.
201. Critchley G, Handa A, Maw A, Harvey A, Harvey MR, Corbett CR. Complications of varicose vein surgery. *Ann R Coll Surg Engl* 1997;79:105-10.
202. Hayden A, Holdsworth J. Complications following re-exploration of the groin for recurrent varicose veins. *Ann R Coll Surg Engl* 2001;83:272-3.
203. Corder AP, Schache DJ, Farquharson SM, Tristram S. Wound infection following high saphenous ligation: a trial comparing two skin closure techniques: subcuticular polyglycolic acid and interrupted monofilament nylon mattress sutures. *J R Coll Surg Edinb* 1991;36:100-2.
204. Hirsemann S, Sohr D, Gastmeier K, Gastmeier P. Risk factors for surgical site infections in a free-standing outpatient setting. *Am J Infect Control* 2005;33:6-10.
205. Biswas S, Clark A, Shields DA. Randomised clinical trial of the duration of compression therapy after varicose vein surgery. *Eur J Vasc Endovasc Surg* 2007;33:631-7.
206. Mekako AI, Chetter IC, Coughlin PA, Hatfield J, McCollum PT. Randomized clinical trial of co-amoxiclav versus no antibiotic prophylaxis in varicose vein surgery. *Br J Surg* 2010;97:29-36.
207. Atkin GK, Round T, Vattipally VR, Das SK. Common peroneal nerve injury as a complication of short saphenous vein surgery. *Phlebology* 2007;22:3-7.
208. Rudstrom H, Bjorck M, Bergqvist D. Iatrogenic vascular injuries in varicose vein surgery: a systematic review. *World J Surg* 2007;31:228-33.
209. van Rij AM, Chai J, Hill GB, Christie RA. Incidence of deep vein thrombosis after varicose vein surgery. *Br J Surg* 2004;91:1582-5.
210. Scavee V. Transilluminated powered phlebectomy: not enough advantages? Review of the literature. *Eur J Vasc Endovasc Surg* 2006;31:316-9.
211. Arumugasamy M, McGreal G, O'Connor A, Kelly C, Bouchier-Hayes D, Leahy A, et al. The technique of transilluminated powered phlebectomy: a novel, minimally invasive system for varicose vein surgery. *Eur J Vasc Endovasc Surg* 2002;23:180-2.

212. Shamiyeh A, Schrenk P, Huber E, Danis J, Wayand WU. Transilluminated powered phlebectomy: advantages and disadvantages of a new technique. *Dermatol Surg* 2003;29:616-9.
213. Passman MA, Dattilo JB, Guzman RJ, Naslund TC. Combined endovenous ablation and transilluminated powered phlebectomy: is less invasive better? *Vasc Endovasc Surg* 2007;41:41-7.
214. Franz RW, Knapp ED. Transilluminated powered phlebectomy surgery for varicose veins: a review of 339 consecutive patients. *Ann Vasc Surg* 2009;23:303-9.
215. Blomgren L, Johansson G, Dahlberg-Akerman A, Norén A, Brundin C, Nordström E, Bergqvist D. Recurrent varicose veins: incidence, risk factors and groin anatomy. *Eur J Vasc Endovasc Surg* 2004;27:269-74.
216. Disselhoff BC, der Kinderen DJ, Kelder JC, Moll FL. Randomized clinical trial comparing endovenous laser with cryostripping for great saphenous varicose veins. *Br J Surg* 2008;95:1232-8.
217. Perrin MR, Guex JJ, Ruckley CV, dePalma RG, Royle JP, Eklof B, et al. Recurrent varices after surgery (REVAS), a consensus document. *Cardiovasc Surg* 2000;8:233-45.
218. Fischer R, Chandler JG, De Maeseener MG, Frings N, Lefebvre-Vilarbedo M, Earnshaw JJ, et al. The unresolved problem of recurrent saphenofemoral reflux. *J Am Coll Surg* 2002;195:80-94.
219. Allegra C, Antignani PL, Carlizza A. Recurrent varicose veins following surgical treatment: our experience with five years follow-up. *Eur J Vasc Endovasc Surg* 2007;33:751-6.
220. Perrin MR, Labropoulos N, Leon LR, Jr. Presentation of the patient with recurrent varices after surgery (REVAS). *J Vasc Surg* 2006;43:327-34.
221. Fischer R, Linde N, Duff C, Jeanneret C, Chandler JG, Seeber P, et al. Late recurrent saphenofemoral junction reflux after ligation and stripping of the greater saphenous vein. *J Vasc Surg* 2001;34:236-40.
222. Campbell WB, Vijay Kumar A, Collin TW, Allington KL, Michaels JA. Randomised and economic analysis of conservative and therapeutic interventions for varicose veins study. The outcome of varicose vein surgery at 10 years: clinical findings, symptoms and patient satisfaction. *Ann R Coll Surg Engl* 2003;85:52-7.
223. Geier B, Stücker M, Hummel T, Burger P, Frings N, Hartmann M, et al. Residual stumps associated with inguinal varicose vein recurrences: a multicenter study. *Eur J Vasc Endovasc Surg* 2008;36:207-10.
224. Geier B, Mumme A, Hummel T, Marpe B, Stücker M, Ascitutto G, et al. Validity of duplex-ultrasound in identifying the cause of groin recurrence after varicose vein surgery. *J Vasc Surg* 2009;49:968-72.
225. Ascitutto G, Ascitutto KC, Mumme A, Geier B. Pelvic venous incompetence: reflux patterns and treatment results. *Eur J Vasc Endovasc Surg* 2009;38:381-6.
226. Müller MA, Mayer D, Seifert B, Marinček B, Willmann JK. Recurrent lower-limb varicose veins: effect of direct contrast-enhanced three-dimensional MR venographic findings on diagnostic thinking and therapeutic decisions. *Radiology* 2008;247:887-95.
227. Creton D, Uhl JF. Foam sclerotherapy combined with surgical treatment for recurrent varicose veins: short term results. *Eur J Vasc Endovasc Surg* 2007;33:619-24.
228. Pittaluga P, Chastanet S, Locret T, Rousset O. Retrospective evaluation of the need of a redo surgery at the groin for the surgical treatment of varicose vein. *J Vasc Surg* 2010;51:1442-50.
229. van Groenendaal L, van der Vliet JA, Flinkenflögel I L, Roovers EA, van Sterkenburg SM, Reijnen MM, et al. Treatment of recurrent varicose veins of the great saphenous vein by conventional surgery and endovenous laser ablation. *J Vasc Surg* 2009;50:1106-13.
230. van Groenendaal L, Flinkenflögel L, van der Vliet JA, Roovers EA, van Sterkenburg SM, Reijnen MM. Conventional surgery and endovenous laser ablation of recurrent varicose veins of the small saphenous vein: a retrospective clinical comparison and assessment of patient satisfaction. *Phlebology* 2010;25:151-7.
231. O'Hare JL, Parkin D, Vandenbergroek CP, Earnshaw JJ. Mid term results of ultrasound guided foam sclerotherapy for complicated and uncomplicated varicose veins. *Eur J Vasc Endovasc Surg* 2008;36:109-13.
232. Kabnick LS. Varicose veins: endovenous treatment, In: Cronenwett JL, Johnston KW, editors. *Rutherford's vascular surgery*. 7th ed. Philadelphia: Saunders; 2010, p. 871-88.
233. van den Bos RR, Milleret R, Neumann M, Nijsten T. Proof-of-principle study of steam ablation as novel thermal therapy for saphenous varicose veins. *J Vasc Surg* 2011;53:181-6.
234. De Felice E. Shedding light: laser physics and mechanism of action. *Phlebology* 2010;25:11-28.
235. Puglisi R, Tacconi A, Sanfilippo S. L'application du laser ND-YAG dans le traitement du syndrome variqueux. In: *Proceedings of the 10th World Congress of Phlebologie: Strasbourg, 25-29 September 1989*. Paris: John Libbey Eurotext; 1992. p. 677-9.
236. Boné C. Tratamiento endoluminal de las varices con laser de diodo: estudio preliminar. *Rev Patol Vasc* 1999;5:35-46.
237. Navarro L, Min RJ, Boné C. Endovenous laser: a new minimally invasive method of treatment for varicose veins: preliminary observations using an 810 nm diode laser. *Dermatol Surg* 2001;27:117-22.
238. Min RJ, Zimmet SE, Isaacs MN, Forrestal MD. Endovenous laser treatment of the incompetent greater saphenous vein. *J Vasc Interv Radiol* 2001;12:1167-71.
239. Proebstle TM, Lehr HA, Kargl A, Espinola-Klein C, Rother W, Bethge S, et al. Endovenous treatment of the greater saphenous vein with a 940-nm diode laser: thrombotic occlusion after endoluminal thermal damage by laser-generated steam bubbles. *J Vasc Surg* 2002;35:729-36.
240. Proebstle TM, Mochler T, Gül D, Herdemann S. Endovenous treatment of the great saphenous vein using a 1,320 nm Nd:YAG laser causes fewer side effects than using a 940 nm diode laser. *Dermatol Surg* 2005;31:1678-83.
241. Proebstle TM, Mochler T, Herdemann S. Reduced recanalization rates of the great saphenous vein after endovenous laser treatment with increased energy dosing: definition of a threshold for the endovenous fluence equivalent. *J Vasc Surg* 2006;44:834-9.
242. Kalra M, Gloviczki P. Fifteen years ago laser was supposed to open arteries, now it is supposed to close veins: what is the reality behind the tool? *Perspect Vasc Surg Endovasc Ther* 2006;18:3-8.
243. Kabnick LS. Outcome of different endovenous laser wavelengths for great saphenous vein ablation. *J Vasc Surg* 2006;43:88-93.
244. Mozes G, Kalra M, Carmo M, Swenson L, Gloviczki P. Extension of saphenous thrombus into the femoral vein: a potential complication of new endovenous ablation techniques. *J Vasc Surg* 2005;41:130-5.
245. Puggioni A, Kalra M, Gloviczki P. Superficial vein surgery and SEPS for chronic venous insufficiency. *Semin Vasc Surg* 2005;18:41-8.
246. Puggioni A, Kalra M, Carmo M, Mozes G, Gloviczki P. Endovenous laser therapy and radiofrequency ablation of the great saphenous vein: analysis of early efficacy and complications. *J Vasc Surg* 2005;42:488-93.
247. Van den Bussche D, Moreels N, De Letter J, Lanckneus M. Endovenous laser treatment for primary varicose veins. *Acta Chir Belg* 2006;106:32-5.
248. van den Bos R, Arends L, Kockaert M, Neumann M, Nijsten T. Endovenous therapies of lower extremity varicosities: a meta-analysis. *J Vasc Surg* 2009;49:230-9.
249. Stirling M, Shortell CK. Endovascular treatment of varicose veins. *Semin Vasc Surg* 2006;19:109-15.
250. Christenson JT, Gueddi S, Gemayel G, Bounameaux H. Prospective randomized trial comparing endovenous laser ablation and surgery for treatment of primary great saphenous varicose veins with a 2-year follow-up. *J Vasc Surg* 2010;52:1234-41.
251. Chandler JG, Pichot G, Sessa CS, Schuller-Petrović S, Kabnick LS, Bergan JJ. Treatment of primary venous insufficiency by endovenous saphenous-vein obliteration. *Vascul Surg* 2000;34:201-13.
252. Chandler JG, Pichot O, Sessa C, Schuller-Petrović S, Osse FJ, Bergan JJ, et al. Defining the role of extended saphenofemoral junction ligation: a prospective comparative study. *J Vasc Surg* 2000;32:941-53.
253. Pichot O, Sessa C, Chandler JG, Nuta M, Perrin M. Role of duplex imaging in endovenous obliteration for primary venous insufficiency. *J Endovasc Ther* 2000;7:451-9.

254. Merchant RF, Pichot O; Closure Study Group. Long-term outcomes of endovenous radiofrequency obliteration of saphenous reflux as a treatment for superficial venous insufficiency. *J Vasc Surg* 2005;42:502-9.
255. Morrison N. Saphenous ablation: what are the choices, laser or RF energy. *Semin Vasc Surg* 2005;18:15-8.
256. Lurie F, Creton D, Eklof B, Kabnick LS, Kistner RL, Pichot O, et al. Prospective randomised study of endovenous radiofrequency obliteration (closure) versus ligation and vein stripping (EVOLVEs): two-year follow-up. *Eur J Vasc Endovasc Surg* 2005;29:67-73.
257. Merchant RF, DePalma RG, Kabnick LS. Endovascular obliteration of saphenous reflux: a multicenter study. *J Vasc Surg* 2002;35:1190-6.
258. Hingorani AP, Ascher E, Markevich N, Schutzer RW, Kallakuri S, Hou A, et al. Deep venous thrombosis after radiofrequency ablation of greater saphenous vein: a word of caution. *J Vasc Surg* 2004;40:500-4.
259. Puggioni A, Marks N, Hingorani A, Shiferson A, Alhalbouni S, Ascher E, et al. The safety of radiofrequency ablation of the great saphenous vein in patients with previous venous thrombosis. *J Vasc Surg* 2009;49:1248-55.
260. Proebstle TM, Vago B, Alm J, Göckeritz O, Lebard C, Pichot O, et al. Treatment of the incompetent great saphenous vein by endovenous radiofrequency powered segmental thermal ablation: first clinical experience. *J Vasc Surg* 2008;47:151-6.
261. Gohel MS, Davies AH. Radiofrequency ablation for uncomplicated varicose veins. *Phlebology* 2009;24 (suppl 1):42-9.
262. Lawrence PF, Chandra A, Wu M, Rigberg D, DeRubertis B, Gelabert H, et al. Classification of proximal endovenous closure levels and treatment algorithm. *J Vasc Surg* 2010;52:388-93.
263. Kabnick LS. Complications of endovenous therapies: statistics and treatment. *Vascular* 2006;14(suppl 1):S31-2.
264. Myers KA, Jolley D. Outcome of endovenous laser therapy for saphenous reflux and varicose veins: medium-term results assessed by ultrasound surveillance. *Eur J Vasc Endovasc Surg* 2009;37:239-45.
265. Rasmussen LH, Bjoern L, Lawaetz M, Blemings A, Lawaetz B, Eklof B, et al. Randomized trial comparing endovenous laser ablation of the great saphenous vein with high ligation and stripping in patients with varicose veins: short-term results. *J Vasc Surg* 2007;46:308-15.
266. Min RJ, Khilnani N, Zimmet SE. Endovenous laser treatment of saphenous vein reflux: long-term results. *J Vasc Interv Radiol* 2003;14:991-6.
267. Huisman LC, Bruins RM, van den Berg M, Hissink RJ. Endovenous laser ablation of the small saphenous vein: prospective analysis of 150 patients, a cohort study. *Eur J Vasc Endovasc Surg* 2009;38:199-202.
268. Knipp BS, Blackburn SA, Bloom JR, Fellows E, Laforge W, Pfeifer JR, et al. Endovenous laser ablation: venous outcomes and thrombotic complications are independent of the presence of deep venous insufficiency. *J Vasc Surg* 2008;48:1538-45.
269. Pannier F, Rabe E, Maurins U. First results with a new 1470-nm diode laser for endovenous ablation of incompetent saphenous veins. *Phlebology* 2009;24:26-30.
270. Doganci S, Demirkilic U. Comparison of 980 nm laser and bare-tip fibre with 1470 nm laser and radial fibre in the treatment of great saphenous vein varicosities: a prospective randomised clinical trial. *Eur J Vasc Endovasc Surg* 2010;40:254-9.
271. Darwood RJ, Theivacumar N, Dellagrammaticas D, Mavor AI, Gough MJ. Randomized clinical trial comparing endovenous laser ablation with surgery for the treatment of primary great saphenous varicose veins. *Br J Surg* 2008;95:294-301.
272. de Medeiros CA, Luccas GC. Comparison of endovenous treatment with an 810 nm laser versus conventional stripping of the great saphenous vein in patients with primary varicose veins. *Dermatol Surg* 2005;31:1685-94; discussion: 1694.
273. Vuylsteke M, Van den Bussche D, Audenaert EA, Lissens P. Endovenous laser obliteration for the treatment of primary varicose veins. *Phlebology* 2006;21:80-7.
274. Kalteis M, Berger I, Messie-Werndl S, Pistrich R, Schimetta W, Pölz W, et al. High ligation combined with stripping and endovenous laser ablation of the great saphenous vein: early results of a randomized controlled study. *J Vasc Surg* 2008;47:822-9; discussion: 829.
275. Pronk P, Gauw SA, Mooij MC, Gastra MT, Lawson JA, van Goethem AR, et al. Randomised controlled trial comparing sapheno-femoral ligation and stripping of the great saphenous vein with endovenous laser ablation (980 nm) using local tumescent anaesthesia: one year results. *Eur J Vasc Endovasc Surg* 2010;40:649-56.
276. Thakur B, Shalhoub J, Hill AM, Gohel MS, Davies AH. Heterogeneity of reporting standards in randomised clinical trials of endovenous interventions for varicose veins. *Eur J Vasc Endovasc Surg* 2010;40:528-33.
277. Nicolini P. Treatment of primary varicose veins by endovenous obliteration with the VNUS closure system: results of a prospective multicentre study. *Eur J Vasc Endovasc Surg* 2005;29:433-9.
278. Rautio T, Ohinmaa A, Perälä J, Ohtonen P, Heikkinen T, Wiik H, et al. Endovenous obliteration versus conventional stripping operation in the treatment of primary varicose veins: a randomized controlled trial with comparison of the costs. *J Vasc Surg* 2002;35:958-65.
279. Pichot O, Kabnick LS, Creton D, Merchant RF, Schuller-Petroviae S, Chandler JG, et al. Duplex ultrasound scan findings two years after great saphenous vein radiofrequency endovenous obliteration. *J Vasc Surg* 2004;39:189-95.
280. Eklof B. Fire, foam, and knife for varicose veins: what have randomized, prospective trials taught us? Available at: <http://www.veithsymposium.org/pdf/vei/3132.pdf>.
281. Stotter L, Schaaf I, Bockelbrink A, Baurecht HJ. Radiowellenobliteration invaginierendes oder Kryostripping: Welches Verfahren belastet den Patienten am wenigsten? *Phlebologie* 2005;34:19-24.
282. Hinchliffe RJ, Ubhi J, Beech A, Ellison J, Braithwaite BD. A prospective randomised controlled trial of VNUS closure versus surgery for the treatment of recurrent long saphenous varicose veins. *Eur J Vasc Endovasc Surg* 2006;31:212-8.
283. Perala J, Rautio T, Biancari F, Ohtonen P, Wiik H, Heikkinen T, et al. Radiofrequency endovenous obliteration versus stripping of the long saphenous vein in the management of primary varicose veins: 3-year outcome of a randomized study. *Ann Vasc Surg* 2005;19:669-72.
284. Gale SS, Lee JN, Walsh ME, Wojnarowski DL, Comerota AJ. A randomized, controlled trial of endovenous thermal ablation using the 810-nm wavelength laser and the ClosurePLUS radiofrequency ablation methods for superficial venous insufficiency of the great saphenous vein. *J Vasc Surg* 2010;52:645-50.
285. Shepherd AC, Gohel MS, Brown LC, Metcalfe MJ, Hamish M, Davies AH. Randomized clinical trial of VNUS ClosureFAST radiofrequency ablation versus laser for varicose veins. *Br J Surg* 2010;97:810-8.
286. Almeida JI, Kaufman J, Göckeritz O, Chopra P, Evans MT, Hoheim DF, et al. Radiofrequency endovenous ClosureFAST versus laser ablation for the treatment of great saphenous reflux: a multicenter, single-blinded, randomized study (RECOVERY study). *J Vasc Interv Radiol* 2009;20:752-9.
287. Marston WA, Owens LV, Davies S, Mendes RR, Farber MA, Keagy BA. Endovenous saphenous ablation corrects the hemodynamic abnormality in patients with CEAP clinical class 3-6 CVI due to superficial reflux. *Vasc Endovasc Surg* 2006;40:125-30.
288. McPheeters HO. Treatment of varicose veins; a twenty-five year reflection. *Minn Med* 1956;39:271-5.
289. Sigg K, Zelikovski A. "Quick treatment": a modified method of sclerotherapy of varicose veins. *Vasa* 1975;4:73-8.
290. Sigg K. [Treatment of varicose veins and their complications]. *Dermatologica* 1950;100:315-20.
291. Fegan WG, Fitzgerald DE, Beesley WH. A modern approach to the injection treatment of varicose veins and its applications in pregnant patients. *Am Heart J* 1964;68:757-64.
292. Fegan WG. Continuous compression technique of injecting varicose veins. *Lancet* 1963;2:109-12.
293. Tournay R. [Indications for a single sclerosing therapy or diphasic combined surgery-sclerosing therapy in varicose veins]. *Zentralbl Phlebol* 1965;87:133-42.
294. Wallois P. [Incidents and accidents in the sclerosing treatment of varicose veins and their prevention]. *Phlebologie* 1971;24:217-24.
295. Hobbs JT. The treatment of varicose veins: a random trial of injection-compression therapy versus surgery. *Br J Surg* 1968;55:777-80.

296. Guex JJ, Allaert FA, Gillet JL, Chleir F. Immediate and midterm complications of sclerotherapy: report of a prospective multicenter registry of 12,173 sclerotherapy sessions. *Dermatol Surg* 2005;31:123-8.
297. Vin F, Chleir F, Allaert FA. An ambulatory treatment of varicose veins associating surgical section and sclerotherapy of large saphenous veins (3S technique). Preliminary study with results at one year. *Dermatol Surg* 1996;22:65-70.
298. Schadeck M, Allaert F. [Ultrasonography during sclerotherapy]. *Phlebologie* 1991;44:111-29.
299. Cornu-Thenard A, de Cottreau H, Weiss RA. Sclerotherapy: continuous wave Doppler-guided injections. *Dermatol Surg* 1995;21:867-70.
300. Cabrera Garido JR, Cabrera Garcia Olmedo JR, Olmedo DG. Nuevo metododel de esclerosis en las varices tronculares. *Patol Vasculares* 1995;4:55-73.
301. Cabrera J, Redondo P, Becerra A, Garrido C, Cabrera J Jr, García-Olmedo MA, et al. Ultrasound-guided injection of polidocanol microfoam in the management of venous leg ulcers. *Arch Dermatol* 2004;140:667-73.
302. Cabrera J, Cabrera J Jr, Garcia-Olmedo MA, Redondo P. Treatment of venous malformations with sclerosant in microfoam form. *Arch Dermatol* 2003;139:1409-16.
303. Cavezzi A, Tessari L. Foam sclerotherapy techniques: different phases and methods of preparation, catheter versus direct injection. *Phlebology* 2009;24:247-51.
304. Frullini A, Cavezzi A. Sclerosing foam in the treatment of varicose veins and telangiectases: history and analysis of safety and complications. *Dermatol Surg* 2002;28:11-5.
305. Coleridge-Smith P. Foam and liquid sclerotherapy for varicose veins. *Phlebology* 2009;24 (suppl 1):62-72.
306. Smith PC. Chronic venous disease treated by ultrasound guided foam sclerotherapy. *Eur J Vasc Endovasc Surg* 2006;32:577-83.
307. Barrett JM, Allen B, Ockelford A, Goldman MP. Microfoam ultrasound-guided sclerotherapy of varicose veins in 100 legs. *Dermatol Surg* 2004;30:6-12.
308. Breu FX, Guggenbichler S, Wollmann JC 2nd. European Consensus Meeting on Foam sclerotherapy 2006, Tegernsee, Germany. *Vasa* 2008;37(suppl 71):1-29.
309. Breu FX, Guggenbichler S. European Consensus Meeting on Foam Sclerotherapy, April 4-6, 2003, Tegernsee, Germany. *Dermatol Surg* 2004;30:709-17.
310. Bountouroglou DG, Azzam M, Kakkos SK, Pathmarajah M, Young P, Geroulakos G, et al. Ultrasound-guided foam sclerotherapy combined with sapheno-femoral ligation compared to surgical treatment of varicose veins: early results of a randomised controlled trial. *Eur J Vasc Endovasc Surg* 2006;31:93-100.
311. Kakkos SK, Bountouroglou DG, Azzam M, Kalodiki E, Daskalopoulos M, Geroulakos G, et al. Effectiveness and safety of ultrasound-guided foam sclerotherapy for recurrent varicose veins: immediate results. *J Endovasc Ther* 2006;13:357-64.
312. Tessari L, Cavezzi A, Frullini A. Preliminary experience with a new sclerosing foam in the treatment of varicose veins. *Dermatol Surg* 2001;27:58-60.
313. Bergan J. Sclerotherapy: a truly minimally invasive technique. *Perspect Vasc Surg Endovasc Ther* 2008;20:70-2.
314. Bergan J, Cheng V. Foam sclerotherapy for the treatment of varicose veins. *Vascular* 2007;15:269-72.
315. O'Hare JL, Stephens J, Parkin D, Earnshaw JJ. Randomized clinical trial of different bandage regimens after foam sclerotherapy for varicose veins. *Br J Surg* 2010;97:650-6.
316. Guex JJ. Complications and side-effects of foam sclerotherapy. *Phlebology* 2009;24:270-4.
317. Goldman MP, Sadick NS, Weiss RA. Cutaneous necrosis, telangiectatic matting, and hyperpigmentation following sclerotherapy: etiology, prevention, and treatment. *Dermatol Surg* 1995;21:19-29.
318. Bergan JJ, Weiss RA, Goldman MP. Extensive tissue necrosis following high-concentration sclerotherapy for varicose veins. *Dermatol Surg* 2000;26:535-41.
319. Ceulen RP, Sommer A, Vernooij K. Microembolism during foam sclerotherapy of varicose veins. *N Engl J Med* 2008;358:1525-6.
320. Munavalli GS, Weiss RA. Complications of sclerotherapy. *Semin Cutan Med Surg* 2007;26:22-8.
321. Bush RG, Derrick M, Manjoney D. Major neurological events following foam sclerotherapy. *Phlebology* 2008;23:189-92.
322. Picard C, Deltombe B, Duru C, Godefroy O, Bugnicourt JM. Foam sclerotherapy: a possible cause of ischaemic stroke? *J Neurol Neurosurg, Psychiatry* 2010;81:582-3.
323. Forlee MV, Grouden M, Moore DJ, Shanik G. Stroke after varicose vein foam injection sclerotherapy. *J Vasc Surg* 2006;43:162-4.
324. Morrison N, Cavezzi A, Bergan J, Partsch H. Regarding Stroke after varicose vein foam injection sclerotherapy. *J Vasc Surg* 2006;44:224-5.
325. Wright D, Gobin JP, Bradbury AW, Coleridge-Smith P, Spoelstra H, Berridge D, et al. Varisolve polidocanol microfoam compared with surgery or sclerotherapy in the management of varicose veins in the presence of trunk vein incompetence: European randomized controlled trial. *Phlebology* 2006;21:180-90.
326. Regan JD, Gibson KD, Rush JE, Shortell CK, Hirsch SA, Wright DD. Clinical significance of cerebrovascular gas emboli during polidocanol endovenous ultra-low nitrogen microfoam ablation and correlation with magnetic resonance imaging in patients with right-to-left shunt. *J Vasc Surg* 2011;53:131-70.
327. Morrison N, Neuhardt DL, Rogers CR, McEown J, Morrison T, Johnson E, et al. Comparisons of side effects using air and carbon dioxide foam for endovenous chemical ablation. *J Vasc Surg* 2008;47:830-6.
328. Chant AD, Jones HO, Weddell JM. Varicose veins: a comparison of surgery and injection-compression sclerotherapy. *Lancet* 1972;2:1188-91.
329. Kern P, Ramelet AA, Wütschert R, Hayoz D. Compression after sclerotherapy for telangiectasias and reticular leg veins: a randomized controlled study. *J Vasc Surg* 2007;45:1212-6.
330. Goldman MP. Treatment of varicose and telangiectatic leg veins: double-blind prospective comparative trial between aethoxyskerol and sotradecol. *Dermatol Surg* 2002;28:52-5.
331. Rabe E, Otto J, Schliephake D, Pannier F. Efficacy and safety of great saphenous vein sclerotherapy using standardised polidocanol foam (ESAF): a randomised controlled multicentre clinical trial. *Eur J Vasc Endovasc Surg* 2008;35:238-45.
332. Yamaki T, Nozaki M, Iwasaka S. Comparative study of duplex-guided foam sclerotherapy and duplex-guided liquid sclerotherapy for the treatment of superficial venous insufficiency. *Dermatol Surg* 2004;30:718-22.
333. Cabrera J, Cabrera J Jr, Garcia-Olmedo MA. Sclerosants in microfoam: a new approach in angiology. *Int Angiol* 2001;20:322-9.
334. Darvall KA, Sam RC, Bate GR, Silverman SH, Adam DJ, Bradbury AW, et al. Changes in health-related quality of life after ultrasound-guided foam sclerotherapy for great and small saphenous varicose veins. *J Vasc Surg* 2010;51:913-20.
335. Rigby KA, Palfreyman SJ, Beverley C, Michaels JA. Surgery versus sclerotherapy for the treatment of varicose veins. *Cochrane Database Syst Rev* 2004:CD004980.
336. Perrin M. Endovenous radiofrequency ablation of saphenous vein reflux. The VNUS Closure procedure with Closurefast. An updated review. *Int Angiol* 2010;29:303-7.
337. Enzler MA, van den Bos RR. A new gold standard for varicose vein treatment? *Eur J Vasc Endovasc Surg* 2010;39:97-8.
338. Gay J. On varicose disease of the lower extremities and its allied disorders: skin discoloration, induration, and ulcer: being the Lettsomian Lectures delivered before the Medical Society of London in 1867. London: John Churchill and Sons; p. 1868.
339. Homans J. The operative treatment of varicose veins and ulcers, based upon a classification of these lesions. *Surg Gynecol Obstet* 1916;22:143-58.
340. Linton RR. The communicating veins of the lower leg and the operative technic for their ligation. *Ann Surg* 1938;107:582-93.
341. Cockett FB, Jones DE. The ankle blow-out syndrome: a new approach to the varicose ulcer problem. *Lancet* 1953;1:17-23.

342. Cockett FB. The pathology and treatment of venous ulcers of the leg. *Br J Surg* 1955;43:260-78.
343. Dodd H. The diagnosis and ligation of incompetent ankle perforating veins. *Ann R Coll Surg Engl* 1964;34:186-96.
344. Hauer G. Endoscopic subfascial discussion of perforating veins: preliminary report. *Vasa* 1985;14:59-61.
345. O'Donnell TJ Jr. Surgical treatment of incompetent perforating veins. In: Bergan JJ, Kistner RL, editors. *Atlas of venous surgery*. Philadelphia: W. B. Saunders Company; 1992, p. 111-24.
346. Gloviczki P, Cambria RA, Rhee RY, Canton LG, McKusick MA. Surgical technique and preliminary results of endoscopic subfascial division of perforating veins. *J Vasc Surg* 1996;23:517-23.
347. Conrad P. Endoscopic exploration of the subfascial space of the lower leg with perforator interruption using laparoscopic equipment: a preliminary report. *Phlebology* 1994;9:154-7.
348. Bergan JJ, Murray J, Greason K. Subfascial endoscopic perforator vein surgery: a preliminary report. *Ann Vasc Surg* 1996;10:211-9.
349. Wittens CH, Pierik RG, van Urk H. The surgical treatment of incompetent perforating veins. *Eur J Vasc Endovasc Surg* 1995;9:19-23.
350. Gloviczki P, Bergan JJ, Rhodes JM, Canton LG, Harmsen S, Ilstrup DM, et al. Mid-term results of endoscopic perforator vein interruption for chronic venous insufficiency: lessons learned from the North American subfascial endoscopic perforator surgery registry. *The North American Study Group. J Vasc Surg* 1999;29:489-502.
351. Masuda EM, Kessler DM, Lurie F, Puggioni A, Kistner RL, Eklof B, et al. The effect of ultrasound-guided sclerotherapy of incompetent perforator veins on venous clinical severity and disability scores. *J Vasc Surg* 2006;43:551-6.
352. Whiteley MS, Holdstock JM, Price BA, Smith JJ, Gallagher TM. Radiofrequency ablations of the refluxing great saphenous vein system, Giacomini veins, incompetent perforating veins using VNUS closure and TRLOP technique. *Phlebology* 2003;18:52.
353. Peden E, Lumsden A. Radiofrequency ablation of incompetent perforator veins. *Perspect Vasc Surg Endovasc Ther* 2007;19:73-7.
354. Hingorani AP, Ascher E, Marks N, Shiferson A, Patel N, Gopal K, et al. Predictive factors of success following radio-frequency styler (RFS) ablation of incompetent perforating veins (IPV). *J Vasc Surg* 2009;50:844-8.
355. Marks N, Hingorani A, Ascher E. New office-based vascular interventions. *Perspect Vasc Surg Endovasc Ther* 2008;20:340-5.
356. O'Donnell TF. The role of perforators in chronic venous insufficiency. *Phlebology* 2010;25:3-10.
357. Elias S. Percutaneous ablation of perforating veins. In: Gloviczki P, editor. *Handbook of venous disorders: guidelines of the American Venous Forum*. 3rd ed. London: Hodder Arnold; 2009, p. 536-44.
358. Gloviczki P, Bergan JJ, editors. *Atlas of endoscopic perforator vein surgery*. London: Springer; 1998.
359. Proebstle TM, Herdemann S. Early results and feasibility of incompetent perforator vein ablation by endovenous laser treatment. *Dermatol Surg* 2007;33:162-8.
360. Pierik EG, van Urk H, Hop WC, Wittens CH. Endoscopic versus open subfascial division of incompetent perforating veins in the treatment of venous leg ulceration: a randomized trial. *J Vasc Surg* 1997;26:1049-54.
361. Kianifard B, Holdstock J, Allen C, Smith C, Price B, Whiteley MS. Randomized clinical trial of the effect of adding subfascial endoscopic perforator surgery to standard great saphenous vein stripping. *Br J Surg* 2007;94:1075-80.
362. van Neer P, Kessels FG, Estourgie RJ, de Haan EF, Neumann MA, Veraart JC, et al. Persistent reflux below the knee after stripping of the great saphenous vein. *J Vasc Surg* 2009;50:831-4.
363. Nelzen O. Prospective study of safety, patient satisfaction and leg ulcer healing following saphenous and subfascial endoscopic perforator surgery. *Br J Surg* 2000;87:86-91.
364. Iafrati MD, Pare GJ, O'Donnell TF, Estes J. Is the nihilistic approach to surgical reduction of superficial and perforator vein incompetence for venous ulcer justified? *J Vasc Surg* 2002;36:1167-74.
365. Kalra M, Gloviczki P, Noel AA, Rooke TW, Lewis BD, Jenkins GD, et al. Subfascial endoscopic perforator vein surgery in patients with post-thrombotic venous insufficiency: is it justified? *Vasc Endovasc Surg* 2002;36:41-50.
366. Kalra M, Gloviczki P. Subfascial endoscopic perforator vein surgery: who benefits? *Semin Vasc Surg* 2002;15:39-49.
367. Bianchi C, Ballard JL, Abou-Zamzam AM, Teruya TH. Subfascial endoscopic perforator vein surgery combined with saphenous vein ablation: results and critical analysis. *J Vasc Surg* 2003;38:67-71.
368. Tawes RL, Barron ML, Coello AA, Joyce DH, Kolvenbach R. Optimal therapy for advanced chronic venous insufficiency. *J Vasc Surg* 2003;37:545-51.
369. Stacey MC, Burnand KG, Layer GT, Pattison M. Calf pump function in patients with healed venous ulcers is not improved by surgery to the communicating veins or by elastic stockings. *Br J Surg* 1988;75:436-9.
370. Rhodes JM, Kalra M, Gloviczki P. The management of incompetent perforating veins with open and endoscopic surgery. In: Gloviczki P, editor. *Handbook of venous disorders: guidelines of the American Venous Forum*. 3rd ed. London: Hodder Arnold; 2009, p. 523-35.
371. Akesson H, Brudin L, Cwikiel W, Ohlin P, Plate G. Does the correction of insufficient superficial and perforating veins improve venous function in patients with deep venous insufficiency? *Phlebology* 1990;5:113-23.
372. Coakley FV, Varghese SL, Hricak H. CT and MRI of pelvic varices in women. *J Comput Assist Tomogr* 1999;23:429-34.
373. Rundqvist E, Sandholm LE, Larsson G. Treatment of pelvic varicosities causing lower abdominal pain with extraperitoneal resection of the left ovarian vein. *Ann Chir Gyn* 1984;73:339-41.
374. Chung MH, Huh CY. Comparison of treatments for pelvic congestion syndrome. *Tohoku J Exp Med* 2003;201:131-8.
375. Beard RW, Highman JH, Pearce S, Reginald PW. Diagnosis of pelvic varicosities in women with chronic pelvic pain. *Lancet* 1984;2:946-9.

Submitted Jan 12, 2011; accepted Jan 15, 2011.